

**Introduction to
Cosmetic Medicine
Workshop**

**Chemical Peels
Botulinum Toxin**

**31 October – 2 November
2018
Brisbane**

Introduction

This seminar is an introduction into chemical facial peels to provide a basis for expanding your practice in the treatment of photodamaged skin. The peels we will deal with range from superficial to medium depth peels. We will also discuss other methods to improve the skin involving the use of retinoic acid, alpha hydroxy acids, broad-spectrum sunscreens and skin bleaches.

Botulinum toxin injection will also be discussed in the treatment of functional facial rhytids.

As we age, our skin goes through certain changes. It thins and loses elasticity, causing small wrinkles and lines to form. In addition, aging skin has a tendency to become blotchy and freckled, especially, in Australia where it has been overexposed in the sun from an early age.

The chemical peel is basically a way to remove damaged superficial layers of skin, exposing a new layer of healthier skin, resulting in a softer, more uniform complexion. In addition, a chemical peel stimulates the growth of new cells, thereby plumping up the skin and helping to tighten it.

There are many different types of peels ranging from superficial to very deep. The Depth of the peel that the skin needs are dependent on the degree of damage to the skin has. In general the more severely damaged the skin is, the deeper the peel you need to improve it.

In the past phenol was used to burn off several layers of skin. These peels could eliminate many facial lines but had a tendency to produce pale and waxy skin. These have been replaced by the use of CO₂ and, more recently, Erbium lasers and are rarely used. However light and medium peels using Trichloroacetic acid (TCA) or Alpha Hydroxy Acids (AHA) create a wonderful freshening effect but won't remove deep lines because they do not penetrate deep enough. However they will significantly help improve fine lines, particularly around the eyes, since they are due to thinning of the skin. In addition these peels do not create a pale or waxy look. On the contrary, they give the complexion a fresh natural look.

Classification of Skin Types

The most widely used classification of skin types is the Fitzpatrick classification.

FITZPATRICK CLASSIFICATION

- I White skin. Always burns, never tans
- II White skin. Usually burns, tans less than average
- III White skin. Sometimes mild burn, tans about average
- IV White. Rarely burns, tans more than average
- V Brown. Rarely burns, tans profusely
- VI Black. Never burns, deeply pigmented

This examines the ability of a patient's skin to tan or burn. This information is helpful in determining which patients will respond well to chemical peeling and which have a high risk of pigmentation abnormalities from peels.

This system, however does not determine the degree of photodamage thereby helping to determine the depth of the peel required.

Glogau Classification

Damage

	<u>Description</u>	<u>Characteristics</u>
Type 1	“No wrinkles”	Early photoaging <ul style="list-style-type: none">• mild pigmentary changes• no keratoses• minimal wrinkles• patient age-20-30s• minimal or no makeup• minimal acne scarring
Type III (advanced)	“Wrinkles at rest”	Advanced Photoaging <ul style="list-style-type: none">• obvious dyschromia, telangiectasias• visible keratoses• wrinkle present even when not moving• Patient age-50s or older• heavier foundation always worn• acne scarring that makeup does not cover
Type IV	“Only wrinkles”	Severe photoaging <ul style="list-style-type: none">• yellow-grey skin colour• prior skin malignancies• wrinkles throughout, no normal skin• Patient age-60s or 70s• makeup cannot be worn-it cakes and cracks• severe acne scarring

CLASSIFICATION OF PHOTODAMAGE

Level 1

Clinical signs are due to alteration in the epidermis only. Most abnormalities are of pigmentation and texture, including freckles, lentigines, and a dull rough skin texture due to increased thickness of the stratum corneum.

Level 2

Clinical signs are due to alterations of the epidermis and papillary dermis and are also related to abnormal pigmentation. Patients with level 2 damage may have all the same clinical signs as level 1 damage. However, the textural and pigmentary changes are more marked. In addition, these patients have actinic keratoses, liver spots (senile lentigines or flat seborrheic keratoses), and a definite increase in wrinkling. This increase in wrinkling is usually seen in the infraorbital area and lateral to the nasolabial groove, where the skin may appear atrophic and grooved.

Level 3

Clinical signs are due to alterations in the epidermis, papillary dermis, and reticular dermis. The most severe form of photodamage, level 3 is associated with many of the clinical changes in level 1 and 2 changes. However, these patients also have marked wrinkling, usually associated with thick leathery appearance and feel, and often a yellowish tint to the skin. In addition, the skin of some patients has a pebbly texture and scattered open comedones.

DYSCHROMIA

The hyperpigmented lesions most commonly seen are ephelides (freckles), lentigines simplex, senile lentigines, seborrheic keratoses, naevi, melasma and post inflammatory hyperpigmentation. To be able to treat these lesions it is important to understand the histology.

Freckles (Ephelides):

Clinical Findings

- Small brown macules on sun exposed areas, which darken with sun exposure.

Histology

- Normal epidermal architecture without elongation of rete ridges
- Increased melanin along the basal cell layer
- Melanocytes normal in number but larger and more dendritic

Lentigines Simplex:

Clinical findings

- Small, evenly pigmented, light to dark brown macules on sun exposed or non sun-exposed areas: similar in appearance to junctional naevi

Histology

- Slight elongation of rete ridges
- Increased melanocytes and melanin in basal region or above
- Melanophages in the upper dermis

Senile (Solar) Lentigines:

Clinical Findings

- Dark brown macules of various sizes on sun exposed areas of older individuals: usually with irregular borders

Histology

- Clublike elongation of rete ridges with possible areas of atrophic epidermis
- More numerous melanocytes with increased melanin
- Melanophages in upper epidermis

Seborrheic Keratoses:

Clinical Findings

- Slightly raised to thickened, light brown to black lesions in various sites: often appear to be “stuck on”

Histology

- Marked increase in thickness of squamous and stratum corneum layers
- Varied amounts of pigmentation, primarily in basal layer but often throughout epidermis

Junctional Naevi:

Clinical Findings

- Well demarcated light to dark brown macules occurring anywhere on the body

Histology

- Numerous single and clustered naevus cells (non dendritic melanocytes) along the dermal-epidermal junction or bulging into the epidermis
- Varied amount of pigment seen in the naevus cells, epidermis and dermal melanophages

Melasma:*Clinical Findings*

- Symmetrical, sharply demarcated, irregular patches of light to dark hyperpigmentation: usually seen on the face

Histology

- Increased melanocytes and melanin in the basal and suprabasal layers
- Dermal melanophages present in various degrees

Postinflammatory Hyperpigmentation:*Clinical Findings*

- Poorly demarcated hyperpigmented macules in areas of previous inflammation

Histology

- Increased melanin in the epidermis with or without dermal melanophages.

Assessment

A Wood's lamp is helpful to help determine the depth of hyperpigmentation and, therefore, assist in deciding the depth of a peel required. A Wood's lamp emits a wavelength 354 nm. Viewed under a Wood's light, areas of epidermal pigmentation become more pronounced or accentuated, whereas areas of deeper dermal hyperpigmentation become less obvious. In simple terms, the worse a patient looks under a Wood's Lamp, the more superficial the pigmentation and the easier it is to correct.

- Always examine in a dark a room as possible. Even a small amount of ambient light makes it significantly more difficult to interpret the pigmentation abnormality and the results of the examination
- The angle of the lamp affects the accentuation of pigmentation. Hold the lamp 10 to 15 cms from the patient's face and rotate your wrist at different angles while examining the area of hyperpigmentation. Changing the angle makes the epidermal accentuation more apparent.
- Areas of hyperpigmentation that are accentuated by the Wood's lamp have epidermal melanin in them. In some cases this melanin extends to the dermis as well. This is not apparent in the clinical view because of the intensified epidermal response to the Wood's lamp. This means that, because of the superficial pigmentation may be obscuring the deeper melanin component, you can never be certain that the removal of the epidermis will completely remove an area of hyperpigmentation accentuated by the Wood's lamp.
- The intensity of the Wood's lamp directly affects the degree of pigmentation accentuation. The battery-powered lamps with only one bulb are definitely not as effective as the lamp with two bulbs that plug into the wall outlet.

REVERSAL OF PHOTODAMAGE USING AT HOME CARE

Sun Avoidance

It is important to stop on-going photo damage. It makes little sense to improve the quality of the skin and then subject it to further damage from chronic ultraviolet (UV) light exposure.

Complete avoidance of sunlight for several years can actually reverse some histologic signs of photodamage. The skin has the ability to repair itself if it is protected from continual photodamage.

In Australia total sun avoidance is difficult if not impossible for most people. Therefore we must settle for the next best thing -sun protection. The concept of sun protection encompasses sun protective clothing (including hats) and sunscreens.

The easiest to use and most reasonable protection for most people is sunscreen. Sunscreen should be worn every day, whether the person is outdoors a little or a lot. Because UV damage is cumulative in its effects, the prevention of even small daily amounts of sun damage over a long period of time can have a profound impact on the total amount of UV-induced damage.

It is also important to consider the type of sunscreen being used. Basically they can be broken down into two types- physical blocks and chemical blocks. *Physical blocks* actually create a physical barrier to the penetration of UV light into the skin. The classic physical block is zinc oxide or titanium dioxide, long popular with lifeguards to protect their noses and lips.

Although physical blocks are effective, they are not cosmetically elegant. Most patients are unwilling to wear these products daily. Recently, some products containing micronized titanium dioxide have become available. When applied these physical blocks do not appear as an opaque cream but rather as a filmy or slightly powdery layer, which most patients find much more acceptable than their old counterparts. The benefits of these products are that they provide very broad-spectrum coverage and are less irritating to sensitive skin types than traditional chemical sunscreens. Nevertheless, sunblocks containing micronized titanium dioxide are still not as cosmetically appealing as the chemical sunscreens and must be applied in a fairly thick layer to work their best.

Chemical sunscreens rely on the absorption of UV light by the active “sunscreens chemical”. Once the absorbing chemical binds to the stratum corneum, it prevents the penetration of UV light into the deeper layers of skin. The most popular sunscreen had been para-aminobenzoic acid (PABA). It has since been replaced by other chemicals because of its tendency to create staining, its fairly high rate of contact allergy, and its inability to block any UVA light.

Newer sunscreens generally contain several active chemical agents in an effort to provide broad-spectrum protection. Most sunscreens are aimed at blocking UVB (280 to 320nm) light, since these wavelengths are thought to be the most carcinogenic. The

sun protection factor (SPF) number on a bottle of sunscreen is actually a measure of how effective the sunscreen is in being able to block erythema induced by UVB light. Research has shown that sunscreens with a SPF of 15 actually block about 92% to 94% of the UVB light. It is important to be aware that most patients apply only half the amount of sunscreen (1 mg/cm²) used by researchers when testing an SPF 2 (mg/cm²) Therefore you need to encourage your patients to apply their sunscreen more thickly than normal for the best protection.

Recently there has been a stronger focus on protection from UVA (320 to 360nm) light as well. On-going studies have suggested that these wavelengths of light are not as benign as they were initially believed to be. Therefore newer sunscreens are often labelled “broad-spectrum coverage” implying that they block UVA as well as UVB light.

Blocking UVA and UVB light is important in treating photodamage. Because UVA light penetrates deeper into the skin than UVB light, it appears to play a significant role in actinically induced wrinkling and damage to the dermis. In addition, UVA light (often called “tanning rays”) can readily intensify hyperpigmentation of the skin, including ephelides, melasma and postinflammatory hyperpigmentation. This effect can be so dramatic that many patients with hyperpigmentation improve significantly when they change from daily use of a UVB blocking sunscreen to daily use of a broad-spectrum sunscreen.

What this all means in basic terms is that **daily use of a broad-spectrum sunscreen is imperative in the treatment of photodamaged skin.** Significant amounts of UVA light pass through window glass, so patients who are indoors near a window all day are still getting UV exposure and should wear a broad spectrum sunscreen. The exact type or brand of sunscreen is a matter of patient and physician preference. Some patients prefer a gel, others a cream, and so forth.

For patients who are subject to extreme amounts of sun exposure (eg skiing mountain climbing, sailing), the application of a broad-spectrum chemical sunscreen each morning should be encouraged, followed 20 to 30 minutes later by the application of a titanium dioxide chemical free sunscreen. This double layer of sunscreens gives patients the benefit of both a chemical and physical screening agent.

Patients should be reminded to wear sunscreen daily on all exposed areas. It is particularly important to apply a broad-spectrum sunscreen to the neck, chest and dorsal hands in addition to the face. Failure to block UVA exposure to these areas makes the skin appear darker and more aged than the skin of the face. This all too familiar look of a youthful face and a weathered chest, neck and hands is the telltale sign of a previous cosmetic procedure having been performed on the face. This is the reason to consider treating the neck, hands and often the chest with a skin care maintenance program similar to that for the face. All areas of visible sun damage should be treated to achieve the best cosmetic results.

Retinoic Acid

Retinoic acid (Stieva A, Retin-A) has really triggered the revolution of the non-surgical treatment for sun-damaged skin. Before the introduction of “Retin-A for Wrinkles,” chemical peels were not particularly popular and there was really no scientifically proven topical therapies for photoaging. When the lay press began to hype retinoic acid for the treatment of aging skin, millions of people went to their doctors in an effort to improve the look of their skin. Once such behaviour became socially acceptable rather than a symbol of extreme vanity, it opened the door to other therapies. Interest in light and medium depth peels exploded as retinoic acid users began to request faster and more significant improvements in their skin than they were achieving on regimens of retinoic acid alone.

Retinoic acid has withstood the test of time. Considerable scientific research shows that it improves the histologic signs of photoaging and photodamage. Most long-term retinoic acid users also demonstrate some degree of clinical improvement in the skin.

There are three problems with retinoic acid:

1. The ability of retinoic acid to correct wrinkles was overplayed in the lay press, the patient began to expect too much from the product. These disappointed patients started the avalanche of negative press about retinoic acid seen in the early 1990s.
2. Retinoic Acid is not a user-friendly drug. Most patients that use it have an initial period of retinoid dermatitis that lasts several weeks. During this time their skin is red, peeling, and sensitive. Once the dermatitis has subsided and the skin has acclimatised to retinoic acid use, a significant number of patients still have occasional mild relapses of dermatitis, usually lasting only 1 or 2 days. This can occur even after several years of use.

In addition, patients who use retinoic acid demonstrate a degree of increased photosensitivity. In some cases, this may be heat-triggered facial flushing rather than true hypersensitivity. However, despite wearing a sunscreen, patients who are outdoors a great deal often complain of a burning sensation on their face while they are in the sun. They are often more comfortable if they wear a sunblock containing a physical blocking agent like titanium dioxide, as well as a hat.

3. Retinoic acid increases capillary arborisation in the dermis. This increased blood flow to the face is often characterised as a healthy rosy glow. However, the same effect may worsen existing facial telangiectasia or may keep the patient's face red. Retinoic acid should be avoided or minimised in patients with ruddy complexions, easy facial flushing, or facial telangiectasia.

Is there a place for retinoic acid in the chemical treatment for photodamaged skin? Absolutely! Research has shown that there are specific retinoid receptors in the skin, leading to the belief that some of the effects of retinoic acid are specific to that agent alone. However, now we have access to other chemicals (including alpha hydroxy acids and superficial chemical peeling agents) retinoic acid does not have to be the mainstay of a treatment program.

What Does Retinoic Acid Actually Do?

HISTOLOGICALLY

Thins and Compacts the Stratum
Corneum

Thickens the epidermis

Reverses keratinocyte atypia

Disperses melanin throughout the
epidermis

Stimulates dermal collagen deposition

Increases glycosaminoglycan deposition

Increases neovascularization in dermis

CLINICALLY

Results in smoother, softer skin texture

Tightens the skin

Improves or eradicates actinic keratoses

Improves blotchy hyperpigmentation

Increases dermal volume and tightens the
skin

Increases dermal volume and tightens the
skin

Gives a pinker, rosy hue to the skin

Using Retinoic Acid:

Retinoic acid is available in the following forms:

Cream - 0.025%, 0.05%, 0.1%

Gel - 0.01%, 0.025%

Liquid - 0.05%

The creams are in a moisturising base, so this form of Retin-A is preferred for patients with mature, dry skin. The gel contains alcohol, and although the percentage of retinoic acid in them is lower than in the creams, the gel base enhances the penetration of the acid. In addition, the gel is drying by nature and often irritates adult skin. The liquid contains alcohol and is very drying, so it is rarely used on adult skin. On occasion, the liquid can be used on patients with very thick sebaceous skin, but most people cannot tolerate it.

There are two approaches to using retinoic acid - conservative and aggressive. In patients with sensitive skin and mild photodamage, a conservative therapy usually works quite well. However, for patients with thick, tough or severe sun damage, a conservative approach is of little or no value.

It is better to prescribe daily use of retinoic acid than alternate-day therapy. Patients who use retinoic acid everyday acclimatise faster and better to it. If a patient has been using retinoic acid routinely and then discontinues it for a week or so, it takes at least 1 to 2 weeks to get him or her reacclimatised to the product. This same phenomenon

exists to a lesser degree in patients who use it every second or third day: they have difficulty stabilizing on retinoic acid and seem to have more trouble, with some degree of chronic peeling. Therefore, **have patients try to use retinoic acid every night, even if it has to be diluted.** Because you do not know what strength retinoic acid the patient will ultimately use, it is wise to initially write a prescription for the smaller 20-g tube rather than the 45-g tube. The best idea is to give the patient a sample to try first.

Patients with Sensitive Skin:

How do you tell if a patient has sensitive skin? The easiest way is to ask them how sensitive their skin is to skin care products, make-ups and soaps. This will usually give you a good idea of their tolerance to topical products.

1. The patient should start by using a pea-sized dab of retinoic acid 0.25% cream at bedtime. The retinoic acid should be applied 20 minutes after gently washing the face with lukewarm water and a mild soap, or non soap cleanser. It is dabbed onto the forehead, nose cheeks and chin, then gently massaged into the skin. Care should be taken to avoid the oral commissures, orbital canthi, and alar creases, since these areas are easily irritated. Initially, the retinoic acid should not be applied to the lower eyelid, and the application should stop at the orbital rim. Although no retinoic acid is applied to the lower eyelid, some of it will migrate or smear there during sleep. This small amount allows the sensitive skin of the lower eyelid time to acclimatise more gradually than the rest of the face. Gradually, the retinoic acid can be applied closer and closer to the eyelid margin until it is within 2 to 3 mm of the lid region.
2. If the patient tolerates this strength of retinoic acid without persistent erythema, peeling or irritation, the strength can be increased to 0.5% cream when the first tube is finished. Later the strength can be increased to 0.1% cream if needed and tolerated.
3. If, on the other hand, the patient has persistent irritation with the use of retinoic acid 0.025% cream, it can be diluted. This is done by mixing an equal pea sized dab of retinoic acid with a pea-sized dab of a fragrance free moisturiser and applying this mixture (now with a concentration of 0.025%) every night at bedtime. If this is still irritating, one dab of retinoic acid can be mixed with two dabs of moisturiser, creating a mixture with a retinoic acid concentration of 0.008%.
4. Some physicians have their patients mix the retinoic acid with a topical corticosteroid cream to decrease inflammation. There is some evidence that retinoic acid can prevent the atrophic effects of chronic steroid use. However, there is no evidence that retinoic can prevent the formation of telangiectasia associated with chronic topical corticosteroid use. In addition, some evidence suggests that chronic retinoic acid use alone can induce telangiectasia. Therefore, it seems prudent to use topical steroid only for short periods.

Aggressive Retinoic Acid Use:

Patients who have used retinoic acid in the past without problems or those who tell you they have “tough skin” do not need to begin therapy on very low dose retinoic acid. As a general rule, start these patients on retinoic acid 0.05% cream at bedtime. The amount applied (pea sized dab) is the same as in patients with sensitive skin. However, these patients can apply the retinoic acid immediately after washing the face, without waiting 20 minutes.

If patients tolerate 0.05% cream easily and without any initial dermatitis, you can rapidly move them to 0.1% cream at bedtime. If they tolerate this strength, you have a few options as to what you can do to increase the effect of the retinoic acid:

1. You can put them on retinoic acid 0.05% liquid. Although this treatment is highly effective in treating acne, it can be rather drying. Despite its increased potential for irritation, there is no evidence that it is more effective in the treatment of photodamaged skin.
2. You can have them apply retinoic acid in the morning as well as at bedtime. This may not be a problem for patients who have minimal sun exposure during the day, but it is difficult for patients who are outdoors a lot.
3. You can have them pretreat their skin with a chemical that will enhance the penetration of retinoic acid before applying it. This includes using a cleanser containing salicylic acid or alpha hydroxy acid. The use of topical abrasive scrubs or masks may also enhance the penetration of retinoic acid by thinning the stratum corneum.

Be sure to caution all patients using retinoic acid that their skin will usually be more sensitive to *anything* that would normally irritate it. It is common to see retinoic acid patients with significant irritation from the use of

- facial chemical depilatories
- hair dye
- hair permanents or straighteners
- facial waxing

It is safest to avoid these products or to discontinue the application of retinoic acid for 5 to 7 days before using them.

Alpha Hydroxy Acids:

Alpha Hydroxy Acids (AHA's) are a group of organic acids that have recently become popular in the treatment of a variety of skin conditions, particularly those characterised by hyperkeratinization. Several of those acids are derived from fruits, so they are often referred to as “fruit acids”. For example, glycolic acid is derived from sugar cane, citric acid from citrus fruits, and malic acid from apples. Although the concept of a natural fruit acid has been exploited by the lay press, it is important that we realise that the glycolic acid available for use on our patients is created in a laboratory and is not squeezed from fruit.

The exact mechanism of action of AHA's is not completely understood. However, it appears that the acids exert specific, separate effects on the epidermis and the dermis.

In the epidermis, the effect is at the level of the stratum granulosum. AHAs create keratinocyte dyscohesion (an ungluing of cells), which causes pathologically sticky cells to become loose, allowing them to shed. This corrects the abnormally thickened stratum corneum, an effect that can persist for up to 14 days after cessation of therapy. This effect is distinctly different than that of other acids, which have a dissolving effect on only the most superficial cells of the stratum corneum. In addition, daily use of AHAs increases epidermal thickness.

The dermal effects of AHAs that have been historically demonstrated are an increase in the deposition of collagen and glycosaminoglycan in the dermis. The effects led to a thickening of the dermis. Presumably this increase in dermal volume creates the reduction in wrinkles and scars often seen in patients using AHAs.

These dermal changes can be seen without any evidence of inflammation. This supports the concept that there may be a specific direct effect of glycolic acid on the skin that is different from the non specific irritant effect.

Several companies manufacture AHA products. Most use glycolic acid, although products containing lactic acid and citric acid are also available. There has been no published studies comparing the relative efficacy of these different AHAs. The question of the effectiveness of varying degrees of neutralisation of AHA products is an important one. Unfortunately, only minimal data about the question is available, despite the claims made by certain companies offering AHA products.

In one small study examining the effect of neutralisation on glycolic acid products, it was shown that solutions containing 10% free glycolic acid were clinically irritating and caused some reactive hyperkeratosis. Solutions containing 10% glycolic acid that was totally neutralised with sodium hydroxide were also irritating but to a significantly lesser degree than those containing only the free acid. Partially neutralised 10% acid was well tolerated and showed some of the beneficial epidermal and dermal changes previously documented with AHA use. Therefore, I encourage the use of partially neutralised glycolic acid products, since they appear to be both well tolerated and effective.

It is also important to consider bio-availability, since the absorption of an active compound can be markedly influenced by the chemical composition of the base it is mixed in. Therefore, having a chemist put 10% glycolic acid in an ordinary face cream will not necessarily create an effect 10% glycolic acid cream as one available from a company experienced in creating and compounding AHA products. My experience with these "homemade" products has been disappointing, suggesting this concept to be true.

Using Glycolic Acid Products:

No one really knows the best way to use glycolic acid products. Normally, when we use an active topical agent to treat a patient's skin, considerable research is available to indicate the most efficacious concentrations, application schedules, and duration of therapy. Unfortunately, no such research exists to help us with AHA's.

The AHA's came on the market at an unusual time. AHA's create some changes in the structure of the skin. If drugs, they have to be appropriately tested before being released to the public. This is a long and expensive process that most companies would prefer to avoid. Rather than subject their AHA products to pharmaceutical testing, many companies put them on the market without making drug claims. Instead they are advertised as "improving the appearance of fine wrinkles". None of the companies sponsor clinical research because if they prove a product works, it becomes a drug!

It is important to keep in mind that the **reason the AHA products are so popular is that patients like them.** Most people who use AHA products notice improvement in their skin. It may only be a softening of rough skin or it may include improved skin colour and wrinkle reduction. Whatever the results, something has changed in the skin; it is not a placebo effect.

Since we really don't know what regimes work best based on research, we are forced to base our decisions on data accumulated from clinical use by patients over the years. Below are recommendations for using AHA products.

Key points to Using AHA Products

1. All AHA products may create transient stinging when first applied to the skin. This is normal and not a cause for concern. Persistent stinging, longer than 30 to 60 seconds, implies too strong a product for the patient's skin (the AHA concentration may be too high, or the PH of the product may be too low).
2. AHA products are available in many forms - including cleansers, astringents, creams, lotions, and gels - so it is easy to select the type of product the patient would prefer to use. For example, oily skinned patients prone to acne usually prefer an astringent or gel rather than a cream. Let the patient tell you what type of product he or she wants to use.
3. It is best to start the patient on a low level product and gradually increase the concentration of the products, rather than top start out on a high strength that may cause irritation. The worst thing you can do is irritate the skin. This destroys the patient's motivation to continue the use of the product.
4. If the patient is currently using retinoic acid without problems, continue its use at bedtime, but add an AHA product in the morning. Again, start with a low concentration product initially.
5. The AHA products rarely cause an increase in photosensitivity, but patients should be cautioned to wear a broad-spectrum sunscreen each morning to protect their newly improved skin.
6. Patients using AHA's usually build up a tolerance to any irritation they may initially experience. Research has shown that using 12% lactic acid salt

(LacHydrin) for several weeks causes the skin to become less reactive to an irritant, sodium lauryl sulfate, than skin untreated with lactic acid.

Almost all patients can tolerate 8% to 10% AHA products to start with. If a patient has a history of very sensitive skin start with 4% glycolic acid cream or 5% lactic acid once daily and increase it to twice daily after several days if there is no evidence of irritation.

For patients with normal skin, start with a product they can use easily. If they are using a night cream, substitute a cream that contains AHA's. If they do not like to wear any lotions, creams or gels, start them on an AHA cleanser or astringent once or twice a day. Because most patients interested in AHA products have photoaged skin, they often have some type of dyschromias with hyperpigmented lesions. These patients do extremely well on a combination of AHA mixed with hydroquinone.

Once patients use their products for 6 to 8 weeks, they should be re-examined. If they are tolerating the products well and are showing signs of clinical improvement, you may elect not to change the regimen. If they are tolerating the products but showing minimal or no clinical improvement, you need to make the regimen more aggressive. This is usually done by following one or more of these suggestions:

- Increasing the concentration of glycolic acid to 12% to 15% twice a day
- Adding retinoic acid at bedtime to the regimen
- Adding an AHA cleanser or astringent twice a day before applying the cream, lotion or gel.
- Trying a series of glycolic acid peels

Although most patients show skin improvement on a regimen of AHA's, the degree of improvement may not be sufficient (even with AHA peels). In these cases, the use of more aggressive peeling agents may be needed to achieve the desired results. However, because AHA products and peels have such low morbidity, it is reasonable to try them before moving to more aggressive treatments with higher morbidity.

Recommended Alpha Hydroxy Acid Products:

MD Formulations - glycolic acid 10% to 12%
Neo Strata
Gly Med

Where to find these products is listed in the appendices

Combination Therapy:

Studies have shown that retinoic acid and AHA's can create similar histologic changes in the skin, including

- a thinner stratum corneum
- a thicker epidermis
- increased glycosaminoglycan deposition
- increased collagen deposition

If retinoic acid and AHA's work on different receptors in the cells, a combination of both products would have the possibility of giving a more marked histologic change than either product alone.

During the past few years an ever increasing number of patients have been using combinations of retinoic acid and AHA creams as part of their daily maintenance programs. This type of combination is perhaps more effective than using either product alone. It also gives the physician the ability to maximise patient benefits while limiting side effects, since lower concentrations of each product can be used if they work synergistically.

Retinoic acid and glycolic acid can be used together safely and with no real increase in the irritation of the skin. It is even possible that long term use of glycolic acid may decrease the skins ability to become irritated, thereby allowing the addition of retinoic acid to the daily regimen. In 1992, Lavker *et al* demonstrated that the use of 12% ammonium lactate twice daily for 2 weeks decreased the skins reaction to a known irritant, sodium laurel sulfate. Granted, this study was performed with lactic acid, not glycolic acid, but these two AHA's appear to have similar effects. It seems reasonable to assume that glycolic acid may decrease the skins re-activity as well. Therefore, when using retinoic acid and glycolic acid creams on the same patient, start the glycolic acid product first; then after 2 weeks of AHA use, add retinoic acid.

There are several key points to remember when designing a combination regimen for your patient:

Do not mix retinoic acid and AHA cream together. No one has examined whether mixing retinoic acid and AHA creams together creates a product which is clinically effective. It may be possible that the mixture becomes "inactivated" or the diffusion coefficient is significantly altered, preventing the active ingredients from penetrating the skin. Therefore it is best to do one of the following:

1. Use retinoic acid at bedtime and AHA in the morning.
2. Use the AHA twice a day and retinoic acid only at night, but wait for an hour after the nighttime AHA treatment before applying the retinoic acid
3. Use a twice-daily AHA product with a base that is a solution or a gel so it penetrates rapidly into the skin. Apply this product and wait until it dries fully (5 to 10 minutes), then apply retinoic acid at bedtime.

Always start with low concentrations first, then increase their concentration over time. Because both retinoic acid and AHA's increase the penetration of other chemicals used on the skin, it appears that lower doses of both products give results

that are comparable to high doses of either product alone, but with decreased potential side effects

If the patient has a ruddy complexion or has dilated facial capillaries, minimise retinoic acid use. Long-term retinoic acid use can increase facial telangiectasia. No evidence suggests that long term AHA use creates a similar effect. Therefore, in patients at risk of facial erythema and telangiectasia, it is prudent to use little or no retinoic acid and to use more aggressive regimen of AHA's.

If the patient has problems of photosensitivity and retinoic acid use, minimise retinoic acid use. Some patients who spend a great deal of time outdoors may complain about photosensitivity with retinoic acid use, even if they wear a daily sunscreen. In these, lowering the retinoic acid's concentration or even discontinuing its use while increasing the concentration of AHA products may still provide clinical improvement, but with much less photoreactivity.

Select the appropriate vehicle (base) for each patient's skin. or any long term topical therapy to be effective, patients must be willing to use the products long term. If a patient has dry skin and you give him products in a drying vehicle (like a solution or some gels), the skin will become drier and probably irritated. Conversely, if a patient has thick oily skin and you give him or her two or three creams to apply each day, the skin will feel greasy and the patient may not want to use these products. Therefore, be sure to select the appropriate vehicle for each patient.

Once the patient is on a daily regime with both products, the skin must be allowed time to improve. Most patients will begin to notice

1. improvement in skin texture
2. reduction in pore size in 3 to 6 weeks
3. improvements in mottled pigmentation in 6 to 12 weeks
4. improvements in wrinkles in 8 to 24 weeks

If a patient is tolerating the regimen well and getting significant clinical improvement, there is no need to change. If, on the other hand, a patient shows little clinical improvement, the regimen needs to be more aggressive. Usually, The easiest way to increase a regimen is to the concentration of AHA first. Because most people can tolerate AHA's better than retinoic acid, it makes sense to increase these products first. This allows the patient to have the potential for better results with a decreased risk of side effects. If the patient can tolerate and increased concentration of AHA's but still fails to improve the next step would be to increase the level of retinoic acid. The constant upward adjustment of concentrations allows you to maximise the patient's benefits.

After six months or so, most patients have reached a plateau of improvement. If their results are acceptable to both of you, they should stay on maintenance therapy. Maintenance therapy does not have to be aggressive as the initial therapy. If patients are comfortable with their daily regime, it is best to leave them on it (now an ingrained habit). If they have some level of irritation with their regimen, decreasing the concentration of one or both products should allow them to maintain improvement without side effects.

At this time, we know that using retinoic acid once or twice a week maintains the histologic improvement achieved from long term daily retinoic use. However, we do not know whether the same effect is true for AHA's. Thus, it is best to maintain daily use of AHA products but to decrease the concentration if the patient experiences irritation.

Other Non-Peel Methods:

With the popularity of the retinoic acid and the AHA's for skin rejuvenation, there has been an ever increasing demand to know how these products work. Many people have hypothesized that these products are irritants that induce increased cellular turnover. Those who disagree state that although patients have increased histological evidence of increased cellular turnover, they do not always show evidence of irritation (inflammation).

In 1989, Wilhelm and colleagues showed that the daily application of a known chemical irritant, sodium lauryl sulfate, to the skin of the volar forearm created about 50% reduction in the turnover time of the stratum corneum compared with the turnover time of skin treated with water. This is rather strong evidence that mitotic activity can be increased by daily applications of an irritant before there is clinical evidence of inflammation. However, all patients exhibited clinical evidence of inflammation within 10 days of using the product. This reaction is not seen in patients using AHA's or low dose retinoic acid, who may show histological evidence of an increased cellular growth without any clinical evidence of inflammation during months of use.

A study by Marks and associates compared the histologic of retinoic acid on photodamaged skin of the forearm with the histologic effects of similar skin treated with an abrasive agent. Biopsy specimens from both treatment areas failed to show any significant inflammation. However, they did demonstrate similar effects of increased epidermal thickness and increased keratinocyte production. The productive question raised by this study is whether these histologic changes, previously attributed to retinoic acid, are nonspecific effects that can be replicated with irritants and abrasives.

On a less scientific note, does it really matter what the mechanism of action is? Obviously, understanding the true mechanism of action is important so that better therapies can be devised in the future, but until that time... If the photodamage can be improved by any of these non-peel methods, we should be happy that we have several therapies at our disposal.

GLYCOLIC ACID PEELS

THE STEPS OF THE CLINICAL FORMULA PEELING SYSTEM ARE:

- One week, twice daily use of a 10-15% AHA prior to the first peel procedure
- Thorough cleansing of patients skin with an effective astringent (Patient should arrive with clean, make-up free skin).
- Application of an adequate amount of Glycolic Acid Peel for appropriate time.
- Thorough removal of peel with ice water.
- Use of restorative emollient until skin returns to near normal appearance.
- Maintenance with daily application of 10-15% AHA Home Care Formulation.

The length of the exposure and frequency of the peels will be based on the results that the patient and physician hope to achieve. Factors included in this system are the condition for which the peel is being used: the patient's acceptability to possible 'downtime' and the speed of the results desired by the patient.

PRE-PEEL DISCUSSION WITH PATIENT.

Approximately one - two weeks prior to scheduling the procedure, it is appropriate to have a consultation with the patient to discuss the following areas:

1. MEDICAL HISTORY

Review medical history with particular regard to the following:

- **Prior Photosensitivity:** After a peel the skin will be more vulnerable. Any prior photosensitivity could be exacerbated.
- **Allergies:** A history of any allergies may indicate the patient's skin will be very reactive to the peel procedure.
- **History of Atopic skin reactions, eczema, seborrheic dermatitis or other sensitivities** could indicate that the patient has very sensitive or reactive skin.
- **Collagen disease/auto immune disease:** This is an area with uncertainties in regard to possible interactions with glycolic acid peel. Therefore, a peel procedure is not recommended.
- **Medications used:** Anticoagulant uses may heal more slowly or, if a deeper peel inducing epidermolysis is performed the risk of bleeding exists.

2. PRODUCTS/TREATMENTS BEING USED

Because of the potential of some products/treatments to increase the reactivity of the skin, patients should be questioned about the recent use of:

Electrolysis
Waxing
Depilatories
Masks
Prior peels or dermabrasion
Hair dyeing treatment
Permanent wave or straightening treatments
Tretinoin
Loofah or other types of exfoliation

At least one week should pass following the use of any of these treatments/products before the peel is done. Each of them could increase the reactivity of skin to glycolic acid.

3. EXCLUSION TO PEELS:

Specific exclusion to glycolic acid peels include:

Active herpes simplex
Warts
Accutane use within six months
Recent surgery (healing wounds)
Recent radiation treatment
Insufficient solar protection
History of hypertrophic or keloidal scarring
Cryotherapy/cryosurgery within one month prior

4. PATIENTS/PHYSICIANS EXPECTATIONS

A discussion with the patient to establish appropriate patient expectations is critical.

It is important to establish:

A. What the patient wants to achieve:

- improvement of fine lines and/or coarse lines
- improvement in skin texture
- improvement in scars
- improvement in pigmentation irregularities
- improvement in skin brilliance or skin tone
- improvement in pore size

- B. What are the areas of the face where the patient sees the condition that needs improvement?
- C. How rapidly does the patient need/want to see improvement?
- D. Is the patient willing to have a 'downtime' (be out of circulation)? If so, for how long? Or does the patient want to be back to his/her daily routine tomorrow?
- E. Is scabbing acceptable or unacceptable to the patient?
- F. Has the patient seen post-peel photographs of other patients with his/her skin type (race, condition, and sensitivity)?

On the basis of the information gathered in this discussion with consideration given to the patients age, skin type, condition, area of the face or body being treated and historical compliance to medical treatment, the timing for the procedure is established.

5. INSTRUCTIONS FOR THE DAY OF THE PEEL.

Patients should be reminded to present on the day of the peel with a fully cleaned face. If possible, no make-up, cologne or after-shave should be applied. Additionally, the patient should avoid shaving on the scheduled day of the procedure, if possible.

MATERIALS FOR THE PEEL.

- Ice bucket for ice water
- Ice
- Fan brush (cotton balls or large cotton tipped applicator may be used)
- Plastic gloves
- Glycolic Acid pads
- Large paper drape
- Paper towels
- Surgical bonnet or hair clips
- Stop watch
- Table or reclining chair
- Electric fan positioned about four feet from patient
- Photographic equipment (if photography is intended)
- Cleansing astringent
- Vaseline
- Small cotton tipped applicators
- Glycolic Acid Peeling Agent
- Restorative, water based, emollient

Communication

Clear communication with the patient regarding what he/she will feel and see during both the procedure and repair/renewal period is critical to the overall success of the process.

Face Peel Procedure

Hair should be secured off the face using clips or surgical bonnet.

The face should be cleansed by the physician using cleansing astringent after all make-up, after shave and cologne have been fully washed off. The objective of the cleansing process is threefold: to remove lipids and cellular debris; to enhance the action of the peel, to modulate the PH of the skin.

Without rinsing the astringent off, the area to be treated should be dried completely. Patting the skin is preferable to rubbing the skin to avoid irritation.

Using a small cotton tipped applicator, Vaseline or petrolatum should be applied to the outer lips and creases of the mouth, nose and eyes to protect these delicate areas during the procedure.

The fan situated about four (4) feet away and aimed toward the patient's face, should be turned on prior to applying the glycolic acid peel.

The stop watch is started and immediate application of the peel is initiated. Begin at the forehead, moving to the cheeks and lower facial areas. Application to the upper lip and nose is done carefully to avoid exposure to lips and nostrils. Continuous reapplication can be done without fear of layering.

Be aware of occlusion sites such as naso-maxillary folds and labio-mandibular folds since these sites are almost always more reactive. If the peel enters the eye it should be removed immediately by ample flushing with water.

When the desired end point is reached the procedure is stopped by flushing the entire face with iced water, which provides final relief from sensations of burning or stinging.

After the peel, a restorative, non-steroid emollient should be applied. It is important to protect the now vulnerable skin and to promote the renewal process. Analgesics can be used to relieve lingering pain. Ice water compresses can be used intermittently for 24-48 hours if swelling occurs.

Determination of Peel Endpoint

Determination of the procedure end-point is dependent on the agreed upon desired result. An end-point is set prior to the start of the procedure. The longer the glycolic acid is left on the skin, the deeper the acid will penetrate (the deeper the peel). The depth of the peel is judged by close observation for visible signs. Increasing depth is seen by:

- erythema (redness) which indicates early dyscohesion of the stratum corneum;

- blanching which indicates epidermolysis;
- desquamation which indicates epidermal detachment

These observable changes serve as signals to stop the peel at - or before - the selected end point by neutralising it with ice water.

During the glycolic acid procedure, the patient will probably feel stinging, itching, burning or discomfort. Each patient's tolerance for these sessions will differ. Monitoring the patient's discomfort can be accomplished simply by asking the patient to verbalise a 0 (no discomfort) to 10 (intense discomfort) scale the level of discomfort they are experiencing. If the patient reaches an 8 to 10 discomfort rating, the procedure should be terminated even if visible signs of the desired end point have not been reached.

WARNING: If the peel goes too far or too long, potential side effects are:

Moderate to severe erythema
 Epidermolysis
 Post inflammatory hypo- or hyper-pigmentation
 Scarring
 Risk of infection
 Long duration of extreme skin sensitivity

Recommended Glycolic Acid Timing

Generally the peel should be left on the skin for 1 minute only for the first treatment and increased to 2 minutes for the next treatment, 3 minutes for the next and so on until you reach 5 minutes. You will need to regularly review the results with the patient in between the treatments and in some cases the maximum time reached for a client may only reach 1-2 minutes (if 'down-time' is unacceptable or the skin is more sensitive)

Examples of the First Three Peels

SKIN TYPE

Time in minutes

	sensitive	normal/sensitive	normal	normal/resistive	resistive
1 st Peel	30 sec	45 sec	1	1	1
2 nd Peel	1	1	2	2	2
3 rd Peel	2	2	2	2	3

JESSNER PEELS.

JESSNER PEELS

PROS:

- It is difficult to overpeel a patient and inadvertently create too deep a wound.
- Jessner's peel creates a good deal of exfoliation (which some patients like to see).

CONS:

- Because the formula contains three active ingredients, there is a greater chance of manufacturing variations.
- There is possible toxicity from resorcinol.
- There is possible toxicity from Salicylic acid.
- For such a superficial peel, it creates a significant amount of stinging and burning and is more uncomfortable than 10% trichloroacetic acid (TCA).
- Jessner's peel creates a good deal of exfoliation (which some patients don't like to see).

JESSNER'S SOLUTION

Jessner's solution is a preparation used for light peels alone or in preparation for a TCA peel. It contains resorcinol, Salicylic acid, and lactic acid, 14% each in ethanol. It is a clear, pale to medium yellow-pink solution with an alcoholic odour. Fresh resorcinol should be used because resorcinol turns dark with exposure to light and air. Salicylic acid is light sensitive. Trace amounts of ferric iron turn Salicylic acid red.

Because Salicylic acid, resorcinol, and lactic acid are solids, computation is weight in volume (W/V). Lactic acid is a liquid that contains, by weight, 85% lactic acid, an alpha hydroxy acid, in water. When the preparation is used, the actual concentration of the lactic acid is 15% less than the labelled percentage of the preparation. A source of error would be to compensate for this by using 18% lactic acid, to provide the equivalent of 14% of lactic acid crystals. This would be an error because the formula calls for 14% lactic acid. If the lactic acid, with a density of 1.2, is measured by volume instead of weight, a preparation 20% stronger than the standard will result. Incorporating both these errors at once would result in a preparation that is over 40% stronger in lactic acid than the standard. Lactic acid absorbs water in moist air, and use of old lactic acid can result in a subpotent preparation.

PERFORMING THE PEEL

Skin Preparation:

As with all peels, the result will be best if the skin is primed before the peel. The goals of skin preparation for all patients set to undergo peeling are as follows:

1. Epidermal turnover should be enhanced
2. The stratum corneum should be thinned.
3. Oil and debris should be removed.

As previously described, skin preparation should consist of the use of retinoic acid, alpha hydroxy acid, or a combination of both. In addition, a bleaching agent should also be used if you are treating the patient for a dyschromia. Remember that this is a light peel, so there is no need to aggressively prime the skin and induce erythema and scaling. If the skin is primed too aggressively, you may inadvertently create a deeper peel than you desire.

Cleaning:

Thoroughly clean the skin to remove make-up, oil and debris. This can be done with alcohol, acetone, Freon, chlorhexidine, or other cleansers. Since this is meant to be a superficial type of peel, there is no need to do an aggressive scrub to clean the skin. The goal is to degrease the skin, not to strip off any remaining stratum corneum.

Application:

In a standard Jessner's peel, the solution is applied to the skin with a 2 x 2 gauze squares. The solution can also be applied with cotton tipped applicators, cotton balls, or many other applicators. Whatever applicator is used, the goal is to apply a uniform layer of acid to the entire area of skin surface to be peeled.

Rubbing the Jessner's solution into the skin with 2 x2 gauze square enhances the penetration of the solution. Therefore, in patients with thick, sebaceous skin, (who are more resistant to the penetration of an acid), applying the solution by aggressively rubbing it into the skin with 2 x2 gauze gives a deeper, more uniform peel. ON the other hand, in patients with thin, sensitive skin, applying the solution with a softer applicator, like a paint brush or cotton-tipped applicator, is a safer approach and one that is more comfortable to the patient.

End of the Peel:

As the depth of a Jessner's peel increases, clinically apparent visual changes occur on the skin surface that correspond to the depths. The first response of the skin to a very superficial Jessner's peel is faint erythema. Associated with this may be a light, powdery-looking whitening of the skin surface. This is not a frost but presumably is the precipitation on the skin of one of the chemicals in the solution. This whitening can be wiped off with your finger, or with water on a cotton ball. It is important to differentiate this whitening from a true frost due to tissue coagulation. This level of

peel (level 1) is very superficial and will create only one or two days of mild flaking or sometimes even no flaking at all.

As the Jessner's solution penetrates deeper with the application of additional coats, erythema becomes more pronounced, often turning bright red, rather than pink. At this time, some fine, pinpoint areas of true white frost usually become visible. Normally, patients feel a mild to moderate amount of burning and stinging with this level of peel. The stinging persists to some degree for 15 to 30 minutes, although on occasion, some patients may feel persistent mild stinging or sensitivity for several hours.

During the next 1 to 3 days, skin subjected to this level of Jessner's peel (level 2) usually develop a persistent mild red-brown coloration, occasionally with the streaking previously mentioned. For 2 to 3 days, the skin feels like a layer of plastic film has been applied, and then it exfoliates for an additional 2 to 4 days. Normally, the skin appears wind-burned, with moderate flaking, but actual peeling is rare.

The next depth (level 3) of Jessner's peeling shows prominent erythema with a significant number of pinpoint areas of frosting, creating a notable whitish look to much of the surface of the skin. Most patients feel a moderate amount of stinging with this level of peel.

During the healing phase, skin undergoing a level 3 Jessner's peel looks and feels similar to that with a level 2 Jessner's peel. However the exfoliation may last as long as 8 to 10 days. Some significant actual peeling may also be seen with this peel, rather than just dry, flaking skin. Crusting and weeping are not seen even a level 3 Jessner's peel, however, since it is an Intraepidermal peel.

The depth of a Jessner's peel is related to the preparation of the skin prior to the peeling, the thickness of the stratum corneum, the sensitivity of the skin, the number of coats of solution applied, and the method of application. In most cases it takes one coat of Jessner's solution to obtain a level 1 peel. It may take two or three coats to achieve a level 2 peel, and three or four coats to achieve a level 3 peel. Obviously there is some variations in these numbers based on the skin type being peeled and other factors previously mentioned, but it is fairly unusual to have one coat of solution create a level 2 or 3 peel. It is far more common that it may take multiple coats of solution to achieve a level 1 peel.

It takes four to six minutes for the full skin reaction to occur after applying the Jessner's solution. Any additional coats of the solution should not be applied until you have waited that long to evaluate the skin and to determine how deep a peel you have already created.

Post-peel Care:

Because most patients feel that their skin is tight and mask like, frequent use of creamy emollients is helpful. The peeling skin may be a little sensitive, so staying with bland, fragrance-free moisturisers like Neutrogena. Certainly, petrolatum and vegetable shortening are alternate emollients, but they are cosmetically unacceptable to most people undergoing a light peel and they preclude the use of make-up. If the

patient has persistent sensitivity or stinging, a mild topical steroid cream or ointment can be used two or three times a day to calm the skin.

During the healing phase of the peel, patients can attempt to wear make-up (after applying a moisturiser) but definitely cannot use scrubs, masks, astringents, toners or retinoic acid or alpha hydroxy acid products. They can resume use of any of these products 48 hours after the peel has healed.

Why Use Jessner's Solution?

The Jessner's peel has been popular to varying degrees for many years. Recently, there has been an upswing of interest in it. Although a Jessner's peel is seldom more effective than a similar depth peel with TCA, it has certain benefits that should be matched to the appropriate patients.

1. They are very superficial and rarely go deeper than you expect. So a Jessner's peel is a safe choice for patients with thin, sensitive skin.
2. They create a fairly uniform depth peel (unlike AHAs)
3. They create a good depth of exfoliation. This is helpful in treating dyschromias, when you are trying to decrease the number of melanin-containing keratinocytes.
4. Since the concentrations of resorcinol in Jessner's solution is low, there is less risk of toxicity than with a regular-strength resorcinol peel.

Caution:

As a general rule, Jessner's peels create flaking of peeling. This is a peel for someone who wants to "peel." Even a light Jessner's peel makes skin shiny and tight for a few days, followed by several days of exfoliation. In addition, the resorcinol component of the peel often creates mild erythema, usually a red-brown colour, which can persist throughout the entire duration of peeling. The erythema and discolouration associated with this peel have a tendency to be streaky, making it more difficult to cover with makeup.

COMPLICATIONS

Because a Jessner's peel is a superficial peel, complications are rare. As stated earlier, it is difficult for a peel to accidentally go too deep with Jessner's solution.

The most common complaints associated with Jessner's peels are not really complications. They are persistent irritation or stinging, streaky erythema, and slow peeling. True complications are allergic reactions, systemic toxicity from resorcinol or Salicylic acid, infection, and persistent erythema.

Allergic Reactions:

Of the three chemicals in the Jessner's solution, resorcinol had been stated to have the greatest tendency to cause allergic reactions. Some physicians advocate patch tests (in the postauricular area) with any resorcinol-containing compound several days

before the actual peel. I have performed many Jessner's peels and have never seen an allergic reaction, with my experience.

Toxicity:

Of the three chemicals found in Jessner's solution, resorcinol and Salicylic acid have the potential to create systematic toxicity. The true potential for toxicity is based on the amount of the chemical absorbed into the skin. Because most of the cleaning and priming of the skin done before the peel is designed to enhance the penetration of the Jessner's solution into the skin, the only real variable is the surface area treated and the number of coats of solution which that are applied.

A review of the literature on Jessner's peels shows repeated references to the need to limit the size of the area treated to prevent resorcinol toxicity. In reality, Salicylic acid toxicity (salicylism) is the limiting factor. Even when peeling the face, neck, and chest with several coats of Jessner's solution, the safety profile is quite good. However, salicylism has been seen with simultaneous Jessner's peeling of the face, chest, arms and lower legs.

Infection:

The chances of an intraepidermal wound becoming infected are remote. Therefore an uncomplicated Jessner's peel should not become infected. If a patient excessively rubs his or her peeling skin or accidentally traumatises it, however, the wound may be extended into the dermis, increasing the potential for infection.

If a wound becomes infected, treatment should include local wound care in conjunction with topical and systemic antibiotics.

Persistent Erythema:

In a small number of patients, some degree of erythema is present in areas for several weeks after the peel. This mild erythema from superficial peels, which fluctuates in intensity during the day, is not cause for concern. It is not the same as the deeply red or violaceous persistent erythema that can complicate medium depth peels, leading to hypertrophic scarring.

The degree of erythema changes throughout the day. It is usually at its best in the morning when the patient first arises, and worsens with face washing, exercise, and consumption of hot beverages, alcohol, and spicy foods. Basically anything that enhances blood flow to the face worsens the erythema.

Erythema is a rare complication of Jessner's peels and is always self-limited. Usually, the patient's skin feels normal with no increased sensitivity or tightness. Low-strength topical corticosteroid creams (hydrocortisone 1%) or bland emollients are the only therapy needed other than daily use of sunscreens.

TRICHLOROACETIC ACID PEELS

TCA has become the gold standard of chemical peeling agents. It has been well studied: it is versatile in its ability to create peels of different depths: it is stable, inexpensive and non toxic.

Trichloroacetic acid and Basic Pharmacy.

Major manufacturers do not make TCA solutions in strengths appropriate for peels, physicians must rely on alternative sources. We have our solution made by a local pharmacist (Drews Pharmacy, North Sydney).

Arithmetic and measuring errors, use of old crystals and contamination are potential sources of error for extemporaneously made preparations. If, during preparation the crystals are exposed to the air they absorb water and the final solution is weaker than intended.

Simple arithmetic and weighing or measuring errors are common. A bottle of TCA crystals can be partially used and sit on a pharmacist's shelf for years. Pure crystals such as TCA crystals do not have an expiry date. TCA is deliquescent, so a preparation made from old crystals with absorbed water may be subpotent. Hydrochloric acid is one of the decomposition products of TCA and could be present in old TCA crystals. TCA attacks cellulose, so TCA packaged in glass bottles with paper lined caps can react with the cellulose in the liner, resulting in contamination with unknown decomposition products.

If a physician uses a preparation that he or she makes (or is made by a local pharmacist and always mixed the same way), that preparation would be of a standard for that physician and he would be familiar with the action of that [articular strength]. However, if the physician is going to compare results with, or make alterations of, his technique based on the experience of another operator, a common basis for determining the actual strength of each preparation is essential.

The standard pharmaceutical method for computing strength of a solution in which a solid is dissolved in a liquid is the *weight in volume (W/V) method*. By convention, such a solution is considered W/V even if not specifically indicated or stated. The standard methods of computing the strength of solid incorporated in another solid is Weight in weight (W/W), such as in ointments or creams.

When a physician claims they are using 30% strength, the reader should reasonably conclude that the preparation described contains 30 g of active material in each 100 mls of solution, 3 g/10 mls or 300 mg/1000 mls.

However authors have described several nonstandard methods of computing strengths of TCA preparations, all describing the solutions as a percentage. When one computes the actual W/V percentages, one author's "30%" may be considerably different from another's "30%". One such error is to describe a given percentage as being achieved by adding the same number of grams to 100mL water; for example claiming that 30% = 30 g with 100 mls water. Another error is to compute W/W the strength by adding a volume of water, considering it synonymous with a weight; for example, claiming

30% = 30 g with 70 mls (g) water. It is clear that 30 g dissolved in 100 mls water is not equivalent to 30 g dissolved in 70 mls water.

Another error is to describe the dilution of a saturated solution of TCA as a percentage; for example, claiming that 30 mls of a saturated solution mixed with 30 mls of water provides a 50% TCA solution. The actual W/V concentration actually obtained is not readily apparent. (It is actually about 74% W/V.) If used, such a solution should be labelled as follows:

Saturated solution trichloroacetic acid (USP XXI) 30 mls

Purified water 30 mls
or alternately:

Saturated solution trichloroacetic acid
Purified water equal parts

Although these differences may seem trivial, inconsistencies in calculation have a significant effect on the resultant absolute concentration of the preparation. Because TCA is half again as dense as water, there is not a 1:1 relationship between TCA crystals or solutions and water.

By measuring the final volumes, the W/V concentration actually achieved using these different methods can be calculated and accurately compared.

Standard: 30 g TCA with enough water to make 100 mls solution, or 30% W/V

Aberration: 30 g TCA with 100 mls water makes 116 mls solution, which is the equivalent of 25.9% W/V

Aberration: 30 g TCA with 70 mls water makes 88 mls solution, the equivalent of 34.1% W/V

Aberration: 30 mls of saturated TCA solution (contains 43.23 g TCA) with 70 mls water makes 99 mls solution, or 43.6% W/V

In this example, the variation resulting in the strongest concentration is more than 65% stronger than the weakest.

TCA is not light sensitive, nor does it require refrigeration. Dark brown bottles serve only to impede visualisation of the contents. TCA solution should be clear, colourless, and free of precipitate or particles. They should be prepared from fresh crystals and stored in clear glass or TCA-resistant plastic bottles. Closures should use paper-free cap liners, such as TCA-resistant polyvinyl seal. TCA solutions should be prepared using the weight in volume (W/V) computations. Because compounding has been deemphasized in modern pharmacy training if one is going to have a TCA preparation prepared by a local pharmacist, always specify weight in volume (W/V). Variation induced by use of old crystals and mathematical or computational errors can be avoided by obtaining TCA solutions in the desired concentrations from a supplier specialising in its preparation.

Performing the Peel

Several peeling agents are commonly used to create superficial peels, but TCA is by far the most commonly used agent to create a medium depth peel.

Although TCA is occasionally used to create deep peels, it appears to induce a higher incidence of hypertrophic scarring than phenol. In addition it can create hypopigmentation and a shiny skin surface, similar to that seen with phenol. Therefore deep peeling with TCA does not appear to have much advantage over phenol, with the exception of lack of cardiotoxicity and the fact that TCA may create a bit less hypopigmentation than phenol.

The procedures for superficial, medium, or deep TCA peeling are similar, although the depth of the peel depends on many factors including

- the patient's skin type
- how the skin was primed
- how the acid is applied
- how many layers of acid are applied
- how wet the applicator is with acid

The most important factor is the concentration of the TCA used. Keeping as many of the other variables as constant as possible allows the concentration of the acid to be the fundamental determinant of the peel depth. Therefore, the skin priming and cleansing should be the same for superficial and medium depth TCA peels.

Skin Preparation

The need for skin priming is as important for TCA peels as for other peels discussed. In particular, when performing medium depth peels with TCA, the benefits of priming (ie increased speed of reepithelialization and decreased risk of postinflammatory hyperpigmentation) are even more important. Remember the minimum amount of time needed to prime the skin for a peel is 2 weeks.

Cleaning

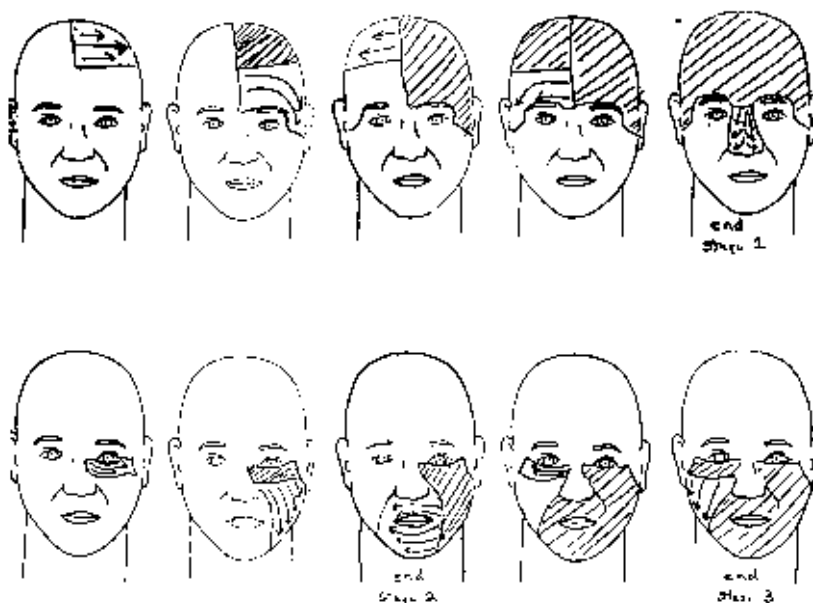
As with other peeling agents the skin should be cleaned well before the peel. Once again, if the skin has been appropriately primed, and the stratum corneum is thin, there should be no need for an aggressive prepeel scrub. The degreasing and cleansing agent can be alcohol, acetone, Hibiclens, or another agent.

Application

Once the skin has been cleaned, the patient should lie down on an examination table with the head elevated about 45 degrees. This angle keeps most patients more comfortable than lying flat on the back, and it seems to decrease the wave of heat associated with the hyperaemic flush of a TCA peel. In addition, with the head elevated 45 degrees, there is less chance of the acid pooling around the eyes after it has been applied to the lower eyelid.

The acid can be applied to the skin with cotton-tipped applicators or 2 x 2 gauze squares. Because it is often necessary to rub the TCA into the skin, a brush is not an effective application device. I prefer to use a 2 x 2 gauze sponge that has been folded into quarters because it allows me to rub the TCA into the skin. Attempting to rub the acid into the skin using a cotton-tip applicator usually breaks the stick. I wet the folded 2 x 2 gauze with enough acid that two or three drops of TCA would drip off when squeezed. It is not dripping wet nor is it squeezed dry.

Begin the application of the acid from the midline to the left side of the forehead, the from the midline to the left side of the forehead. Then apply the acid to the entire nose. At this time, stop the application to allow the patient to cool down and to take an opportunity to observe the nature of the frost developing in the area where TCA has been applied. The second stage of the application begins under the left eye, starting 2 or 3 mm below the lid margin and covering the entire left cheek and perioral area. Here, again stop the application and watch the frost. The third stage is begun below the right eye and extends down the entire right cheek.



Several points should be addressed in regard to the application of TCA:

1. The patient's head should be stabilised with one hand so that you can press fairly hard with your gauze applicator as the acid is applied.
2. When applying the TCA below the eyes and in the 'crows feet' area, you must pull the surrounding skin tight so that

- a. The acid gets to the bottom of the wrinkle
 - b. The wrinkle is temporarily stretched flat, preventing acid from being winked into the eye along the wrinkle by capillary action
3. If you overlap coats of TCA, you will increase the depth of the peel. When using low strengths (less than 25% TCA), this is not much of a problem, but with higher concentrations, an area of accidental overlap can be a problem. Therefore when applying TCA to the skin always follow the same pattern of application, so you know where you have already applied the acid. In addition, it may be helpful to count the number of strokes you apply to each area to ensure the application of similar amounts to all areas.
4. TCA peels work for photodamage. There is rarely any photodamage on the upper eyelid so there is no need to peel that area. However, the peel should be carried through the eyebrows to the edge of the upper orbital rim. Any excess blots of acid left on the eyebrow should be blotted off with a cotton tipped applicator to prevent a deeper peel in the eyebrow area.
5. The peel should be carried into the hairline and 1cm below the jawline to help blend the temporary pigmentation change associated with most peels.

As previously stated, it is imperative that you determine the peel depth required to appropriately treat the patient before beginning the peel. Interpreting acid penetration as you are performing the peel is crucial so that you know when the correct depth has been achieved. Fortunately the depth of a TCA peel correlates well with the intensity of the frost observed on the skin.

TCA is a chemical cauterant, which coagulates proteins in the skin. This is presumably the basis of the formation of white frost seen when TCA is applied to the skin. The deeper the peel performed with TCA, the faster and more intensely white the frost. The intensity of the frost and its associated skin turgor are used to judge the depth of the peel. The level of frost created by superficial and medium depth peels can be classified into four major groups.

Level 0 - no frost: The skin may look and feel a little slick and shiny, but there is no frost and minimum or no erythema. This is a very minimal or superficial peel that, at most, removes the stratum corneum.

Level 1 - irregular light frost: In addition to appearing shiny, the skin shows erythema and some scattered areas of wispy white frost. This is a superficial epidermal peel that creates 2 to 4 days of light flaking.

Level 2 - white frost with pink showing through: The skin has a uniform white colour but there is a strong pink background. This is a full thickness epidermal peel that takes about five days to heal.

Level 3 - solid white frost: The skin has a solid, intense white frost with no pink background showing through. This is a peel that extends into the papillary dermis and takes 5 to 7 days to heal.

These levels of frost are guidelines; they vary a bit from patient to patient. However they define a general pattern that is helpful in determining the depth of the wound that you have created.

In general, TCA is a concentration of 10% to 25% is used as an intraepidermal peeling agent; 30% to 40% is a papillary dermal peeling agent. The actual depth of

penetration of the peeling agent is affected by many other variables, including type and thickness of skin, and how wet the acid applicator was. Therefore, it is always safer to use a lower concentration of TCA, so that if you fail to achieve as deeper peel as you want (you can judge this by examining the frost you created in the first area of your application), you can do several things to increase peel depth:

1. Apply a second coat of acid over the area that has already frosted (it is safest to decrease the strength of TCA in the second coat by 5% to 10% to prevent too deep a peel).
2. When applying the TCA to the next (previously untreated) area on the face;
 - a. Use a gauze sponge that is wetter. It will allow you to apply a greater quantity of acid, which will create a deeper peel.
 - b. Rub the acid-soaked gauze more aggressively into the skin, trying to overlap areas of application.

Once the appropriate frost has been achieved, rinse the patient's face with room temperature water to wash off any excess acid that may remain on the skin. This does not neutralise the TCA; it dilutes any remaining reservoir of acid to prevent a deepening of the peel. (TCA is an aqueous solution, so adding water to it doesn't neutralise it - it dilutes it.)

Some physicians advocate applying ice packs to the skin after the peel to cool the skin and decrease any residual burning. I have found most patients are hypersensitive immediately after the peel and that ice packs are too cold to be comfortable for them. Some patients don't even like the feeling of room temperature water being applied to the skin at this time.

If you do apply water or ice compresses to the skin after a TCA peel, be sure to realise that you will have hydrated the stratum corneum and you cannot go back and reapply more TCA to this area because the acid will be rapidly diluted by the water trapped in the stratum corneum.

After the patient has washed his /her face and patted it dry, apply a cream or an ointment with 1% hydrocortisone to soothe the skin. In theory, applying an occlusive ointment after the peel should function similarly to taping the skin after a peel. This has been shown to be true with phenol, for which applying petrolatum after a peel increases its penetration.

Postpeel Care

Patients can and should expect certain things while healing from TCA peel.

1. The skin will look and feel tight, as if it were covered with a sheet of plastic.
2. Any area of epidermal hyperpigmentation will darken considerably as part of its reaction to the peel.
3. Varying degrees of erythema may be present, often in a blotchy, uneven distribution.
4. Varying degrees of swelling can occur. It is rare to see such oedema with superficial peels, but some oedema is common with papillary dermal peels. The oedema usually peaks 48 hours after the peel.
5. The first areas to begin peeling will be the areas with the most muscle movement (ie, perioral and periorbital areas).
6. The forehead and hairline are usually the last areas to peel.

The layer of necrotic, peeled tissue protects the underlying new tissue. Premature removal of any of this layer increases the risk of persistent erythema, infection, postinflammatory hyperpigmentation and scarring. Therefore, the goal of post peel care is to keep this layer of tissue in place as long as possible and to keep patients comfortable so they will not be tempted to pick or scratch at their skin. It is helpful to tell patients to try not to have any shear forces against their skin, which will create premature peeling. This means a special approach to washing the face and applying emollients:

Washing: Always use a mild soap like neutrogena, or a soap free cleanser like Cetaphil. The patient should gently splash lukewarm water on the face, then lather soap on his/her hands and pat the lather onto the skin. the lather is then rinsed off and the face gently patted dry with a soft towel. **It is not necessary to try to wash off all remnants of the previously applied emollients.**

Applying emollients: When applying any cream or ointment, every effort should be made to pat rather than to rub the product onto the skin. Since this is particularly hard to do with most ointments (they usually are stiff), it is helpful to put a dab of ointment in the palm of the hand and allow it to warm up and liquefy before applying it to the skin.

Depending on the level of the TCA peel, the wound can vary a good deal:

Very superficial intraepidermal peels: The patient should expect some tightness and perhaps mild erythema with associated flaking for 2 to 4 days. During this time, the use of bland emollient is encouraged. The patient can wear make-up and is allowed to shower, but must avoid rubbing his or her face.

Superficial, full-thickness epidermal peels: This level of peel turns dark and unsightly for 4 to 6 days. The skin becomes extremely tight and will fissure and crack if it is not moist enough. These patients normally do not go to work and are unable to wear make-up. They should not shower or swim since it seems to create premature peeling. The use of bland emollients is acceptable for these patients, but their skin is so dry that they need to reapply cream every 1 or 2 hours. Therefore, some patients prefer

using a greasier product, like an ointment. Your choices here include polysporin, bacitracin, petrolatum, and 1% hydrocortisone ointment.

It is important to keep the skin of these patients, moisturised while healing. If it becomes too dry, it may crack, exposing the immature layer of skin. In addition, dry skin has the tendency to become itchy, which increases the chances patients will pick or rub it.

Papillary dermal peels: This level of peel turns dark and unsightly for 5 to 8 days. There is often some mild swelling (particularly in the periorbital area) for the first 48 hours postpeel. Some patients, particularly those with a history of previous facial surgery or of severe sun damage, experience marked oedema of the lower two thirds of their face, which can last 3 to 4 days. This is fairly uncommon and can be helped by sleeping with the head elevated. Ice compresses should be avoided, since they have a tendency to traumatise the peeling skin or to over hydrate it (from the condensation on the outside of the ice packs).

This level of peel feels rather tight for most of the healing phase, and most patients are more uncomfortable with the use of ointments several times a day. 1% hydrocortisone ointment the itching and irritation often associated with these peels.

Patients with papillary dermal peels are quite unattractive while healing. They are unable to wear make-up, and most stay in the home. They often feel a bit fatigued during their healing phase, and they should be encouraged to try to rest and relax as much as possible.

Complications

Unfortunately occasionally some patients will experience complications. It is important to minimise the possible complications. If, despite your best efforts, a complication develops, rapid and appropriate treatment is usually able to correct the complication without an unacceptable cosmetic outcome.

The best way to minimise complications is to avoid performing peels on those at risk for complications, such as the following:

- Patients with histories of poor wound healing
- Patients with history of post inflammatory hyperpigmentation
- Patients who are unable or unwilling to stay out of the sun
- Patients who fail to follow instructions
- Patients with histories of extremely sensitive skin that is easily irritated by most skin care products

There is no reason that these patients can not be peeled. They are a high risk group, however, and you may wish to avoid peeling them or you may opt to use a lighter peel. Remember, the deeper the peel, the greater the risk of complications. Intraepidermal peels have markedly fewer complications than reticular dermal peels. Therefore, when performing a peel on a patient at risk for a complication, you may choose to do several lighter peels rather than one deep one in an effort to produce improvement with little risk of complications.

The most common complications with a chemical peel are:

- tears dripping onto the neck
- premature peeling
- infection
- acneform eruptions
- ecchymosis
- postinflammatory hyperpigmentation
- hypopigmentation
- allergic reactions
- persistent erythema
- scarring

Tears Dripping on the Neck.

Whenever a caustic substance is applied around the eyes or nose, the reflex action is to develop tears. This is a normal, acceptable reflex action helpful in preventing ocular damage if any acid were to get in the eye. A dry eye is unable to dilute the concentration of an acid coming into contact with the eye, whereas the aqueous solution in a tearing eye instantly dilutes the acid, making it less caustic.

Tearing of the eyes causes two primary problems:

1. Tears can drip down the cheeks and dilute the acid still on the cheeks, causing a strip of skin where the peel is more superficial.
2. Tears can drip down the cheek, mixing with the acid there, and continue to drip down onto the neck, causing an area of peeling on the neck. This can be a particularly severe problem if the concentration of the acid is high, since the neck is more easily prone to scarring.

A patient is often unable to notice when his/hers eyes are tearing during the peel. Therefore, it is important to have someone watch the patient's eyes closely during the peel and to dry any tears before they roll down the cheek. This is best done by dabbing the tear with a cotton tipped applicator. It is also possible to put a protective layer of petrolatum on the neck before the peel to guard against any accidental burns on the neck. I recommend against the use of a topical anaesthetic in the eye to decrease tearing, since some degree of tearing is helpful to protect the eye from a burn if acid inadvertently gets in the eye.

If tearing occurs and an obvious strip of lesser peeling is seen on the cheek, additional peeling agent can be applied to that area after drying the tear. If the acid containing tear drips onto the neck, the area should be washed with water to dilute any remaining TCA and then treated like any other post peel area with daily wound care.

Premature Peeling.

Premature peeling can be a problem with any level of peel. The layer of necrotic skin created by the peeling solution functions as a protective bandage, allowing the deeper tissue to heal before being exposed to the elements at the skin surface. Premature removal of this layer, accidental or intentional, exposes a layer of immature tissue that is fragile and possibly not reepithelialized. This can lead to infection, persistent erythema, postinflammatory hyperpigmentation, and scarring.

Although patients generally do not plan on picking at their peeling skin, most do, usually during the last few days of the peel when they are tired of the peeling process and want to accelerate it. Common hallmarks of premature peeling are:

- sharply demarcated areas of bright erythema
- A peel that is completed within 24 to 48 hours of being only half way finished.
- no evidence of old peeling skin anywhere on the face, including the hair line (most patients have small areas of peeling skin in the hairline for 8 to 10 days after the peel)

Areas of premature peeling commonly present either as non-reepithelialized tissue or bright red reepithelialized skin.

Non-Reepithelialized Tissue.

In areas in which peel the peeled skin was removed before the underlying tissue had a chance to reepithelialize, the tissue may look raw on fairly normal but moist and succulent. The first priority in areas of non-reepithelialized tissue is to get the skin to heal and to prevent infections. Aggressive wound care management with the application of topical antibiotics (Bactroban, Silvazine) four times a day is usually all that needed.

An opened wound is an invitation to infection, so I always place patients with areas of non-reepithelialized skin on regimens of oral antibiotics with *Staphylococcus* and *Streptococcus* coverage (eg, cephalosporins, erythromycins, sulfa drugs - all of which work well) until reepithelialization is complete.

Reepithelialized Bright Red Tissue.

Reepithelialized but bright red tissue is healed over, so there is no risk of infection, but it is paper-thin and very fragile. The patient must be instructed to care for the skin as if it were the skin of a new born baby just home from the hospital. No mechanical trauma, including rubbing, is allowed, and a protective layer of an ointment must be applied several times a day.

The potential problems with these areas are postinflammatory hyperpigmentation and persistent erythema. The goal is to prevent the development of these problems by stopping the inflammation before it progresses into a complication.

Patients with reepithelialized, bright red tissue are usually a tender, itchy, or sensitive in these inflamed areas. To decrease inflammation, you can use topical

corticosteroids, oral nonsteroidal antiinflammatory drugs (NSAIDs), or systemic steroids. The oral NSAIDs are usually not particularly helpful in these patients. Although systemic steroids can be effective, it is usually best to try topical therapies first, since they have less risk of complications.

When a topical cortisone is to be applied to inflamed skin, the product base is important. Products with enhanced delivery systems (including propylene glycol) are often irritating to this sensitive skin. As a general rule, ointments are more soothing than creams for the following reasons:

1. They create a better protective barrier than a cream
2. They have fewer chemical additives
3. They enhance the penetration of the cortisone

However, ointments are often unpleasant for patients to wear on the face because it is difficult, if not impossible, to apply makeup on top of an ointment. Because reepithelialized, bright red tissue usually is a complication more than one week after a peel, these patients often need to be back functioning in society at this time. For this reason, I often prescribe a cream with a bland base, the least irritating of which are Elocon 0.1% cream. The erythema usually improves dramatically within in 4 to 7 days. If it fails to improve during this time, I increase the strength of the cortisone creams to a class III topical steroid like Advantan cream or Aristocort A. Although class III topical steroids are generally considered too strong for the face, 5 to 7 days of use should not cause any problems.

Infection.

Fortunately, infections associated with chemical peels are infrequent. As a rule, the incidence of infections increases with the depth of the peel. This is due in part to the fact that peels that form crusts (deep peels) are more prone to bacterial colonisation, leading to infection, than are deep peels that do not form crusts.

Because infections commonly lead to scarring, any suspicion of infection should be treated aggressively. Infections appear to significantly deepen the wound induced by the peeling agent, so rapid treatment intervention is needed to achieve a satisfactory cosmetic outcome.

Several organisms can create the infections associated with peels:

- Common bacterial pathogens - *Staphylococcus* and *Streptococcus* species
- Uncommon bacterial pathogens - *Pseudomonas* and *Enterobacter* species
- Herpes simplex
- *Candida* species

The presentations of early infections with any of these organisms can be strikingly similar. Therefore, a bacterial culture should be taken from any suspicious area. In addition, a Gram stain can provide some useful information rapidly (eg, candidiasis versus gram-positive or gram negative bacteria).

It is helpful to put the patient on a broad spectrum oral antibiotic regimen that covers both gram-positive and gram-negative organisms while you await the culture results. I

routinely use Keflex 500mg twice daily. After the culture and sensitivity results are back, a more specific oral antibiotic can be prescribed.

Appropriate topical wound care of infected areas is vital. Mupirocin ointment (Bactroban) applied four times a day can be helpful both for the positive effect of wound healing of the base and for antibacterial action.

If crusted or necrotic debris is seen on the wound, it must be removed with compresses or gentle mechanical debridement. Compresses containing 0.25% to 5% acetic acid are especially effective against gram-negative bacteria. Gentle mechanical debridement either can be performed by you or your staff in the office or can be accomplished at home by the patient's standing in the shower and letting water run down his/her face (not striking the face directly).

If the patient has a candidal infection, treatment with oral ketoconazole (Nizoral), 200mg per day, is highly effective. In addition, using wet to dry compresses containing distilled water or saline twice daily helps to create an environment less conducive to growth of *Candida* organisms.

Herpetic outbreaks, usually starting on the lip or above the vermilion border, can be triggered by the trauma of a chemical peel. Since the peeling does not have a well developed epidermis, it is not capable of forming a vesicle. Therefore, herpetic infections in peeling patients present with erosions rather than vesicles. The one cardinal sign of herpetic infection is pain. Therefore, as Brody states, "Any painful lesions is herpes until proven otherwise." With the use of prophylactic oral acyclovir (Zovirax), 400 mg three times a day, herpetic outbreaks are rarely a problem. However, occasional patients with no history of herpes labialis may experience outbreaks. These are patients who had previously been infected but had forgotten or were unaware. These patients need immediate oral acyclovir, 400 mg three to four times a day, as well as topical acyclovir applied to the area six times a day. On a rare occasion a patient may not respond well to this dosage, usually because of poor absorption of the drug. In these cases, increase the dosage to of acyclovir to 400 mg five times a day. In summary, the key points about infection are as follows:

1. Superficial and medium depth peels should not create heavy crusts. Assume any area of crusting is an incipient infection and treat appropriately.
2. Perform a culture and a Gram stain of any suspicious area. This will identify bacteria and candidal organisms.
3. Look along the lips and the oral mucosa for signs of thrush.
4. Assume any painful lesion is herpes until proved otherwise, even in patients who do not remember a prior episode of herpes simplex or do not present with vesicles.
5. Treat all infections aggressively with oral and topical antibiotics.
6. If an area fails to grow anything on cultures and continues to worsen despite treatment, consider the possibility of a contact dermatitis to one of the topical agents.

Acneform Eruptions.

A small percentage of patients experience acneform eruptions during or just after the peeling stage. This condition usually appears as multiple tender erythematous follicular papules. These lesions are different from the superficial pustules that can be seen during the healing stage of the peel, which are secondary to follicular occlusions from the emollients and ointments used during the healing phase. True acneform eruptions rarely show pustules and are almost always tender to touch. They respond promptly to antibiotic therapy used to treat normal acne—that is, topical clindamycin or erythromycin, as well as systematic tetracycline, minocycline, or erythromycin. It usually takes five to ten days for acneform eruptions to clear completely.

Ecchymoses.

A small number of patients may develop ecchymoses in the infraorbital area associated with the peel. This is seen only in patients who have pronounced swelling in this area during the healing phase of the peel. Generally, these patients have significant actinic damage and marked atrophy of the skin. Presumably, the periorbital oedema causes a rupture in some of the small vessels of the dermal plexus, creating an ecchymosis. Interestingly, this complication is no more common in patients taking NSAIDs or warfarin (Coumadin) than in those taking no medications.

Ecchymoses are a self-limited complication that has no negative impact on the final result of the peel. Conceptually, it would be possible to develop some residual hyperpigmentation secondary to hemosiderin deposition, but I have never seen this happen.

The treatment for ecchymoses is reassurance and the use of camouflage make up if needed. The discolouration should resolve completely within four to six weeks.

Postinflammatory Hyperpigmentation

Postinflammatory Hyperpigmentation is a condition in which an inflammatory response of the skin leads to the development of subsequent hyperpigmentation. Classically, this has been described as being associated with dark-skinned patients, but it can also occur (with lesser frequency) in patients with light skin and light eyes.

Some authorities have stated that this condition is always triggered by excessive sun exposure after a peel, but I have seen this in patients who have had no postpeel sun exposure at all. Certainly, the underlying tendency for this type of hyperpigmentation seems to be innate in most people who have it. It is rare to see post-inflammatory hyperpigmentation after a peel in a patient who has no history of it from other inflammatory conditions. Therefore, it is helpful to question such patients about their tendency to display hyperpigmentation from minor trauma like cuts or insect bites before performing the peel. If a patient has this tendency, you know there is a high chance that he or she will experience hyperpigmentation from any peel that creates significant inflammation.

When dealing with postinflammatory hyperpigmentation, several key points should be kept in mind:

1. Postinflammatory hyperpigmentation will gradually improve with time with no therapy except sun avoidance.
2. Epidermal postinflammatory hyperpigmentation responds well to a variety of therapies, but dermal postinflammatory hyperpigmentation does not respond so uniformly well.
3. Postinflammatory hyperpigmentation is initiated (and can be worsened) by inflammation. Therefore, all efforts at reducing it must also try to eliminate inflammation.

Postinflammatory hyperpigmentation can develop as quickly as 4 or 5 days after a peel or as long as 2 months afterward. Therefore, when peeling patients at risk for this condition, you must be an astute observer for their entire course of healing.

Treatment

Sunscreen. Because postinflammatory hyperpigmentation is worsened by ultraviolet light (UV), daily use of broad spectrum sunscreens is mandatory. UVA light passes through glass, so the patient needs to block this type of light each day even if rarely outside. Some evidence even suggests that long-wavelengths UVA light can be emitted by certain types of fluorescent light, meaning patients who are never outside may still be at risk for hyperpigmentation if exposed to fluorescent light.

The best sunscreen to use would be a physical blocking sunscreen, but most patients are unwilling to wear these because of their thick, heavy appearance. Certainly, broad spectrum sunscreens with both UVA and UVB blocking chemicals are helpful at screening out a large percentage of UV light. However, wearing a hat or visor in addition to the sunscreen is advisable whenever possible.

Determination of the depth of pigmentation. Always examine the skin using a Wood's lamp. Epidermal pigmentation is accentuated with this light, and dermal pigmentation is deaccentuated. In simpler terms, the more apparent the pigmentation is when viewed with a Wood's lamp, the more superficial the pigmentation. Remember, epidermal hyperpigmentation responds much better to treatment than does dermal hyperpigmentation.

Bleaching Agents. We really have no true bleaching agents to use on the skin. The most commonly used chemicals in the treatment of hyperpigmentation are actually tyrosinase inhibitors, which prevent the conversion of tyrosine to dopa. These chemicals decrease the skin's ability to manufacture melanin, thereby creating a gradual lightening effect.

At this time the most commonly used tyrosinase inhibitors are hydroquinone, kojic acid and azelaic acid. In Australia, hydroquinone is by far the most commonly used bleaching agent, whereas kojic acid is popular in the Far East and azelaic acid is popular in parts of Europe. It is important to realise that none of these products is tremendously effective. The best results are obtained by combining a tyrosine inhibitor with another product that has its own bleaching effect, enhances the penetration of the bleaching agent, or stimulates epidermal growth, thereby

accelerating epidermal cell shedding. Because epidermal cells contain melanin, increasing their shedding decreases the total amount of melanin present in the epidermis, creating less pigmentation and a lightening effect. The most commonly used products to improve the efficacy of a bleaching agent are retinoic acid (Retin A) and alpha hydroxy acids (AHAs).

The standard enhanced bleaching routine is made of a combination of 0.1% retinoic acid cream, 4% hydroquinone with triamcinolone acetonide. However, clinical studies have shown that the steroid is not necessary for the bleaching effect. It has also been shown that using hydroquinone in concentrations higher than 4% is more effective but significantly more irritating to the skin.

The combination of 10% glycolic acid with 4% hydroquinone is as effective to the combination of 0.1% retinoic acid cream and 4% hydroquinone. In addition to its improved efficacy, this combination also has the benefits of not inducing erythema, scaling, inflammation, or photosensitivity (as is often the case with mixtures of retinoic acid and hydroquinone).

Any bleaching agent should be applied to the hyperpigmented areas twice a day. Some degree of clinical improvement should be seen in 3 to 4 weeks, but maximal results take 2 to 3 months.

Repeeling. If the patient's postinflammatory hyperpigmentation is responding slowly to the use of the bleachers and sunscreens, a superficial peel can accelerate the response. The goal of this type of peel is to exfoliate some of the epidermal cells (containing melanin) without creating enough inflammation to trigger another case of postinflammatory hyperpigmentation. This type of peel can be performed with 10% TCA, Jessner's solution, or 50-70% glycolic acid. These should be *conservative* peels. It is safer to perform very light exfoliations every 10-14 days than to peel too deeply, which can recreate postinflammatory hyperpigmentation. **Although light peels are excellent ways of treating postinflammatory hyperpigmentation, many patients with hyperpigmentation due to a peel are not eager to undergo repeeling.**

Hypopigmentation

Any peel that causes actual peeling or exfoliation will lighten the skin. Because melanin is dispersed (in melanosomes) throughout the epidermis, if you shed some cells containing melanin, the total amount of melanin present in the epidermis is reduced, creating a lighter appearance. However, lightening is transient since new melanin is continually formed.

As the level of the peel gets deeper, the degree of lightening or hypopigmentation increases. Remember that melanin is created in melanocytes, which are dispersed along the basal cell layer of the epidermis and extend down the hair follicle. If you remove the entire epidermis, including the basal cell layer, the melanocytes available to migrate into the new epidermis are those in the hair follicle. It takes several months for these melanocytes to effectively repopulate the new epidermis and give it a normal colour. Therefore, a patient undergoing a full thickness epidermal peel will have some degree of hypopigmentation for at least 2 or 3 months.

As the depth of the peel increases, more melanocytes in the hair follicle are damaged or destroyed, leading to greater degrees of hypopigmentation. Also, as more melanocytes are destroyed, an increasing percentage of the resultant hypopigmentation becomes irreversible. Reticular dermal peeling with any peeling

agent always creates some degree of permanent hypopigmentation. However, with deeper peels, repigmentation of the peeled skin can take up to 3 years to reach maximum.

When dealing with hypopigmentation, there are 2 key points to keep in mind:

1. If the patient is using retinoic acid, AHA, hydroquinone, or sunscreen on the face but not the neck, he or she will always be hypopigmented on the face relative to the neck. Therefore it is important in any peel that wounds the basal cell layer or deeper to apply retinoic acid, AHA, hydroquinone, or sunscreen to the neck as well as the face. This will help prevent a line of demarcation in colour. It seems obvious, but many people fail to realise that tanning the neck while protecting the face (with sunscreen) makes the face appear lighter. It is your responsibility to tell the patient to apply sunscreen, as well as post peel maintenance products, to the upper neck as well as the face.
2. Most adults who have actinic damage of the face also have some degree of permanent hyperpigmentation on their skin. It may be obvious on the rest of the body as a permanent “tan line” from a bathing suit or may be visible only on the face and neck with the use of a Wood’s lamp. (Shine a Wood’s lamp on the sun-damaged lateral side of the neck, and contrast it with the sun-spared area directly under the chin).

When you remove the damaged epidermis and replace it with new epidermis, the new skin is really the colour of the normal non-sun-damaged skin. It is not necessarily hypopigmented, just as the skin in the volar forearm is lighter than the skin on the dorsal forearm but is not considered hypopigmented. Therefore any peel that improves sun damage will make the skin a little lighter because healthy skin is lighter than sun-damaged skin. However this degree of lightening should be slight enough not to be a cosmetic liability in most cases of nonphenol medium depth peels.

Allergic Reactions

Fortunately, allergic reactions to chemical peels are rare. As previously mentioned, resorcinol supposedly has the highest incidence of contact allergies. I am unaware of any reported allergies to TCA or Glycolic acid.

The problem with allergic reactions is that they can be difficult to diagnose. Because patients often have erythema and oedema associated with the peel, these symptoms are not useful for diagnosing an allergic reaction. An allergy needs to be recognised and addressed promptly because the skin undergoing an allergic reaction will heal slower with greater risk of complication.

As a general rule, suspect an allergic reaction in the following situations:

1. The patient has significant itching within a few hours of the peel (itching usually doesn’t occur until a few days afterward).
2. The patient has significant oedema within a few hours of a light or medium depth peel (swelling is usually not pronounced until 24-48 hours after the peel and then usually only with peels of the papillary dermis or deeper).

3. Erythema and oedema are seen on the upper neck or in other areas that were not actually peeled
4. Areas of urticaria (hives) appear on the body, or the patient has constriction in the throat with difficulty breathing (this is obviously a medical emergency and demands prompt treatment with adrenalin)

Persistent Erythema

Some degree of erythema is common after almost any type of peel. Although some patients may initially have areas that are bright red, these usually fade into a light red or a pink in 7 to 14 days. At three weeks after the peel, there normally are no areas of significant erythema. Areas that stay red for more than three weeks are often a warning sign that an incipient scar may be forming in that location. These areas are usually dusky red or red-purple rather than the bright red initially seen after the peel. If these areas are left untreated, they usually become indurated and progress into thickened, hypertrophic scars. Areas of persistent erythema 3 weeks after the peel should be viewed as definite precursors to scars and need to be treated aggressively.

The treatment modalities described below are basically the same as those for early hypertrophic scarring. The key here is to be aggressive, but not overly so. Intralesional steroids are not an appropriate therapy at this time, since they will induce atrophy in these patients. There are four possible treatments:

Class I ultra potent topical corticosteroids (betamethasone): these are often capable of reversing persistent erythema in less than two weeks of use.

Silastic Sheeting: These clear sheets are effective in reducing persistent erythema if they are worn continuously for a period of weeks to months. The major draw back is that they are unsightly to wear on the face and are difficult to tape in place there.

Laser: The Photoderm or vascular lasers can reduce persistent erythema. The treatment creates purpura that is rather unsightly for one to three weeks and also the machines are expensive, so each treatment is more expensive than the other modalities mentioned here.

Whatever method you choose should be continued until the erythema resolves.

Scarring.

For most physicians and patients, the worst complication is scarring. Those at risk for scarring include the following:

- Patients with histories of poor healing and keloid formation
- Patients undergoing deep peels
- Patients undergoing second peels without allowing the skin the adequately heal from the first peel or from recent facial surgery
- Patients recently on isotretinoin (Roccutane) therapy
- Patients who develop an infection during the peel

Several types of scars are possible complications from skin peeling:

- Hypopigmented, flat, sheet like areas with a shiny surface and no induration.
- Depressed atrophic areas often with sharply demarcated, shelf like edges.
- Thickened, elevated areas, often with some degree of erythema.
- Severely hypopigmented or erythematous keloid-type scarring, which often causes tension deformities around the mouth or eyes.

Fortunately, scarring is an uncommon complication of chemical peeling. It appears to be directly related to the depth of the peel itself: the deeper the peel the greater the risk of scarring. Reticular dermal peels are far more apt to cause scarring than are papillary dermal peels. An uncomplicated intraepidermal peel should never create a scar.

Many cases of scarring are really secondary to another complications, such as infection, premature peeling, or trauma to the new tissue, rather than a direct complication of the chemical peel. Therefore, careful monitoring of the patient during the healing phase of the peel should allow you to identify and treat any of these predisposing factors before they lead to scarring.

During the past few years, a fair amount of evidence has suggested that patients who have previously taken isotretinoin may have an increased tendency to develop scarring associated with dermabrasion or chemical peels performed after they have finished their isotretinoin therapy. The patients who have displayed this type of scarring have all had a similar type of atypical hypertrophic scar characterised by a stellate scar on the mid cheek. These atypical scars are associated with patients who had taken isotretinoin as long as 2 or 3 years before undergoing chemical peeling.

It would be prudent not to perform any peel for at least 1 year after a patient has completed use of isotretinoin. If the patient has had persistently dry skin since finishing the isotretinoin therapy or has skin fragility, he/she should not undergo peeling with any agent (even the very superficial ones), until the skin has returned to its clinically normal pretreatment state, even if it means waiting 3 to 5 years.

The incidence of this type of scarring is extremely rare, but it has been reported in the literature so you must be aware of it. The exact mechanism of scar formation has not been determined. It may be secondary to decreased collagen remodelling due to decreased collagenase secondary to isotretinoin use.

Regardless of the cause, once scarring has begun to develop, it must be treated as rapidly and aggressively as possible. A mature scar is much more difficult to improve than a developing one. Flat or atrophic scars really don't respond well to any therapy. Fortunately, these are not unsightly as the hypertrophic or keloid scars, which are usually treatable.

At the first sign of persistent erythema or induration in any area after the peel, you should immediately begin treatment with either a class I ultrapotent topical corticosteroid cream applied twice daily or with some type of Silastic sheeting such as Cica-Care (Smith and Nephew). Both these therapies have been highly successful in

reversing erythema and induration and in preventing scar formation. It is far easier for most patients to use the topical corticosteroid twice a day than to wear a Silastic sheet taped to the skin for 24 hours a day. The sheet is unsightly, but it is also difficult to tape into place during the first few weeks after a peel since the surrounding skin is sensitive and fragile at the time.

If you use one of the class I topical corticosteroids, it should be applied twice a day *only to the affected area*. Prolonged use of these products (more than two weeks) has been associated with steroid atrophy and the development of telangiectasias. Fortunately, indurated areas usually respond rapidly, within one week or so. In the case of induration and early scarring, it may take as long as three or four weeks to get complete resolution to the problem. I strongly believe it is worth the risk of steroid atrophy and telangiectasias to prevent scarring, particularly since telangiectasias can be treated with laser, and steroid atrophy can be treated with retinoic acid or AHA's.

Treatment of Scars

If, despite your best efforts, a problem area develops into true scar tissue you have several treatment options, as outlined below.

Silastic sheeting. As previously discussed Silastic sheeting can be effective but is not easy to use on the face. However, if a true scar has developed, the patient may be more highly motivated to wear the sheeting, particularly since it is the least aggressive therapy. Some people experience irritation of folliculitis from the sheeting, but most patients tolerate it well. This is a slow therapy, and both you and the patient need to be prepared to wait several months to achieve the best results.

Intralesional steroids. These are probably the most commonly used therapy in the treatment of hypertrophic scarring. The most popular steroid to use is triamcinolone acetonide (Kenalog). The strength ranges from 1 to 40 mg/mL. When using intralesional steroids, there are several key points to keep in mind:

1. Inject the material directly into the scar, not onto the surrounding tissue. Inadvertent placement of the steroid in the surrounding normal tissue will create atrophy and telangiectasias.
2. The injection works over a two to three week period. Any area of induration present at the end of that time needs to be retreated promptly or it will begin to grow and the scar will recur. The end point of intralesional therapy is a flat supple area with no residual induration.
3. The concentration of the steroid needed is related to the thickness and maturity of the scar. Early, thin scars may respond to triamcinolone acetonide, 2 mg/mL, whereas thick older scars may need 30 to 40 mg/mL. However, it is usually best to start with 3 to 5 mg/mL for early scars and 10 mg/mL for thicker scars. It is important to increase the concentration of the steroid about 5 mg/mL with each successive injection if the scar is failing to respond.
4. Triamcinolone acetonide comes only in concentrations of 10 and 40 mg/mL. These liquids are actually a suspension of triamcinolone crystals rather than a solution. Therefore, they must be shaken thoroughly before being withdrawn from the bottle. The syringe should also be shaken before

the injection to ensure uniform dispersion of the steroid particles. If the syringe is allowed to sit for 5 minutes, the particles will settle out of suspension, possibly inadvertently leading to too weak or too strong an injection. Also, when preparing a suspension in a different concentration than that supplied by the company (19 or 40 mg/mL), you need to dilute the original suspension with sterile water or saline. If you are attempting to create a suspension with a concentration below 10 mg/mL, always begin with the 10 mg/mL strength, not the 40 mg/mL strength. The concentration of active steroid in each particle of 40mg/mL is much greater than that found in the 10 mg/mL strength. Therefore, it is difficult if not impossible to create a suspension of 3 mg/mL by diluting the 40mg/mL suspension. Attempting to do this will create a higher incidence of inadvertent over treatment with resultant atrophy.

Scar excision and revision.

In patients prone to hypertrophic or keloid formation, attempting to surgically excise a scar can be a risky proposition. The new surgical scar may hypertrophy, as happened with the original scar. However, if the scar was created by a secondary complication, such as infection or premature peeling, rather than the nature of how the patients heals from most wounds, there is an excellent chance of successful revision.

Depending on the size and location of the scar, direct excision, Z-plasty, or even grafting may be considered as possible treatments. Because hypertrophic scars often improve spontaneously to a significant degree, it is prudent to **wait a minimum of 6 months after a peel before attempting to surgically revise a scar.**

Cryotherapy.

Some recent research has suggested that cryotherapy using liquid nitrogen can effectively treat hypertrophic scarring. Although this modality is an interesting “non surgical” therapy, it has a high incidence of creating hypopigmentation, an unacceptable complication on the face. Therefore, the usefulness of the procedure may be limited to non facial areas.

Radiation.

Although the popularity of radiation therapy for keloids and hypertrophic scarring has decreased, there may still be occasional times to consider this treatment.

Laser.

The erythema of hypertrophic scarring can be markedly improved with the use of vascular laser or Photoderm. Whether this is due only to an alteration and reduction of blood flow to the scar or some other direct effect on fibroblasts has yet to be elucidated. The possible risks with this therapy are minimal, so this treatment definitely deserves further research.

PATIENT SELECTION

Integrating this information should make it easy to decide on the appropriate treatment program. This is really the most important step in treating the patient. If you choose an inappropriate treatment plan, the patient will get sub-optimal results.

The following few pages will illustrate, with the use of outlines, how your decision-making process should proceed.

Compliant: Rough-textured, dull looking complexion
Due to: Thick stratum corneum
Therapy: Fortunately, this is very easy to treat, and anything you do will improve the skin.

Conservative (No Peeling)

It will take three to six weeks to achieve maximum improvement. The patient needs to thin that stratum corneum and to keep it thin to maintain the improvement. Treatment options are as follows:

- a. Retinoic acid - This should not be used if patient has dry or sensitive skin, facial telangiectasis, or marked sun exposure.
- b. AHA cream, lotion, or gel - This is well tolerated by most patients.
- c. Salicylic acid cleanser - This has a tendency to be a bit drying and is often not effective enough.
- d. Combinations of the above products.

Aggressive (Peeling)

Skin will improve within days of the first peel, but more than one peel may be needed to achieve the best results. (Remember that patients need to be primed before the peel and kept on maintenance therapy afterwards). Peel options include the following:

- a. 10% TCA - End point is level 0 frost; causes some shiny appearance to the skin and possible light exfoliation.
 - b. Jessner's solution - End point is level 1 peel; similar healing appearance to that with TCA
 - c. 50% to 70% Glycolic acid - End point is mild erythema; usually creates no exfoliation
 - d. A single application of any of the above peeling agents with an end point the next level higher will give the patient an excellent result with only one treatment but will create more significant exfoliation and erythema.
-

Complaint: Epidermal Melasma (hyperpigmentation)
Due to: Hormonal influence, genetics, sun exposure
Therapy: The goal of treating epidermal hyperpigmentation is to block the formation of new melanin with a tyrosinase inhibitor and to exfoliate the epidermis to decrease the amount of melanin present in the epidermis. If the hyperpigmentation developed while the patient was pregnant or taking birth control pills and she is no longer pregnant or off the pill, she usually will respond better than if her hormones are still 'adulterated'. If the patient developed Melasma without any underlying cause, the response is variable, since the skin's current 'steady state' is hyperpigmented. Your therapy does not change the skin's desire to return to that steady state, it only suppresses it.

Conservative

No downtime is associated with conservative treatment. Treatment is as follows:

- a. 10% Glycolic acid with 2% to 4% hydroquinone, or 6% AHA with 2% kojic acid and 2% hydroquinone twice a day for 6 weeks with a broad spectrum sun screen applied every morning.
- b. Addition of retinoic acid at bedtime if the skin can tolerate it.
- c. 50% to 70% Glycolic acid peels every two week - End point is mild erythema.
- d. Jessner's solutions or superficial TCA peel every 2 weeks - Works faster than the glycolic acid peels but creates exfoliation.

Aggressive

Patients must be on some type of bleaching agent and a broad-spectrum sun screen before and after their peel (in addition to the medications for priming the skin). Peel options include the following:

- a. Jessner's peels - End point is level three frost; causes heavy exfoliation and moderate erythema
- b. 70% Glycolic acid - End point is patching epidermolysis; causes patching areas of erythema and crusting
- c. 25% to 35% TCA - End point is level two frosting; 5 to 6 days of dark skin and peeling; the most effective option in this category.

Complaint: Epidermal postinflammatory hyperpigmentation
Due to: Reactive process to previous inflammation worsened by sun exposure.
Therapy: The therapy of epidermal postinflammatory hyperpigmentation is the same as that for the epidermal melasma. You need to block the production of new melanin and attempt to exfoliate the epidermis. You must be very careful that you **do not create inflammation with your treatment or it will induce more hyperpigmentation**. Therefore, there really are no safe aggressive therapies for postinflammatory hyperpigmentation, since any aggressive therapy will create erythema.

Conservative

1. If there is any evidence of inflammation, initially use a weak corticosteroid twice daily, then
2. 10% glycolic acid with 2% to 4% hydroquinone, or 6% AHA with 2% kojic acid and 2% hydroquinone once or twice a day, depending on the patient's tolerance; use a broad spectrum sunscreen every morning

If not better, the options are as follows:

- a. Add retinoic acid at bedtime - Low level only; do not create inflammation
- b. 50% Glycolic acid peels every two to three weeks if tolerated - End point is very mild erythema.
- c. Jessner's solution or superficial TCA peel every two to three weeks if tolerated - End point is very mild erythema.

Aggressive

There are no aggressive treatments; all are too risky.

Complaint: Dermal hyperpigmentation
Due to: Melanin in the dermis (determined by Wood's light examination); includes dermal melasma and postinflammatory hyperpigmentation
Therapy: Dermal hyperpigmentation is difficult to treat.

- Topical bleaching agents may be slightly helpful, but they are not sufficient on their own.
 - Papillary dermal peels give variable results
 - Reticular dermal peels can be quite effective (except for variable results with melasma), but they leave some residual hypopigmentation.
-

Complaint: Actinic keratoses

Due to: Atypical keratinocytes in the epidermis, possibly extending down the hair follicle; lesions are usually hyperkeratinic and thus more resistant peels.

Therapy: There are several potential therapies. Your ultimate goal is to destroy the abnormal cells, not just to make the skin feel smooth.

Conservative

With conservative treatment, it can take six to twelve months to achieve a good result. The keratosis may flare up with this therapy and appear worse for several months. Therapy options are as follows:

- a. Retinoic acid in as high a strength as tolerated - Not for patients with sensitive skin, telangiectasias, or marked sun exposure.
- b. AHA in as high a strength as tolerated - Constantly try to increase the strength.
- c. Combination of retinoic acid and AHA
- d. Salicylic acid cleanser - Helps remove the hyperkeratoses associated with actinic keratosis, enhancing the penetration of other agents.
- e. Any of the above with the addition of 5-fluorouracil cream twice a day 1 or 2 days a week for pulse therapy.

Aggressive (Peels)

Although repetitive superficial peels improve the clinical appearance of actinic keratoses, the lesions have a tendency to recur rapidly unless the patient stays on an aggressive regimen of home care products as discussed above. Many patients prefer the aggressive, one-shot deal approach and don't want to stay on home care products. Therefore, I suggest these patients undergo papillary peels to destroy as many of the keratoses as possible at one time. These patients benefit from pre peel 3 - 5 minute scrubs to reduce their hyperkeratoses. Treatment options are as follows:

- a. 30% to 45% TCA (depending on the patients skin type) - End point is level 3 frost; 5 to 8 days of downtime.
 - b. 35% TCA with Jessner's solution, glycolic acid, or solid carbon dioxide - End point and downtime are similar to those with 30% to 45% TCA; you can specifically treat each lesion more aggressively with the first wounding agent to ensure better penetration of the TCA
-

Complain: Fine wrinkles
Due to: Atrophy of the epidermis and dermis; not due to muscle movement or gravitational effects.
Therapy: A small percentage of these patients may achieve a miraculous result with home care products, including retinoic acid and AHA. However, most patients require more aggressive therapy.

Conservative

Options for therapy are as follows:

- a. Retinoic acid at bedtime and an AHA product every morning - Since it appears these two products have a synergistic effect, they should be used together.
- b. Abrasive or salicylic acid cleanser - if the patient can tolerate 0.1% retinoic acid cream at bedtime and a 15% to 20% AHA every morning without irritation, try adding these cleansers to enhance the penetration of the retinoic acid and AHA
- c. Series of 70% glycolic acid peels - Some patients can achieve excellent wrinkle reduction with multiple, very light glycolic acid peels with minimal or no downtime.
- d. Injectable collagen implants into the areas that fail to respond to the options listed above.

Aggressive

These patients need to create epidermal thickening and more collagen and glyco-saminoglycan deposition in the dermis to tighten their skin. I have been routinely disappointed with repeated Jessner peels and superficial TCA peels as therapy for these patients. Treatment is as follows:

- TCA or enhanced TCA peels - End point is level 3 frost in areas of wrinkling; 5 to 8 days of downtime.

KEY POINTS TO REMEMBER

Priming Patients:

- Prime everyone after a peel - for at least 2 weeks, but the longer the better.
- Retin A seems to be a better prep than any other agent (with the possible exception of Roaccutane).
- If the patient can't tolerate Retin A well; try the lowest strength, (0.025% cream). If the patient is still intolerant of Retin A, try using an Alpha Hydroxy Acid.
- If the patient can tolerate Retin A 0.1% cream without any problems you may consider adding on Alpha Hydroxy cream, lotion or gel to intensify their 'priming'.
- Roaccutane is a wonderful drug, but the medical/legal aspects mean that at the present time, specialists can only prescribe it.

Bleaches:

- All patients with dark skin are at risk of post inflammatory hyperpigmentation (so are some fair skinned patients). These patients need to be primed with hydroquinone before the peel (as well as after the peel).
- All patients using peels for disorders of hyperpigmentation, belong on hydroquinone before as well as after the peel.
- Some doctors feel it is not a bad idea to put everyone on a hydroquinone before and after the peel. The only real problems with hydroquinone are possible irritation and allergy, all of which are very rare.

Cleaning Just before a Peel:

- The more aggressively you clean, the deeper the peel will be.
- If you clean with alcohol, acetone, glycolic acid or Jessner's solutions, you will have inadvertently created a much deeper peel.
- Don't use all of the above solutions to prime the skin. Usually alcohol, then 10% glycolic acid, or alcohol then Jessner's solution will create about the same depth peel as an acetone scrub.

The Peel:

- Don't start out doing deep TCA peels - 99% of the complications come from too deep a peel (usually inadvertent).
- It is safest to do 20-30% TCA peels for your first few peels.

POST PEEL PROBLEMS:

If the patient has multiple complication, approach one at a time, starting with the most potentially dangerous. The worst complication is infection. If there is an area of prematurely peeled skin or non epithelialized skin be sure to have the patient on P.O and topical antibiotics. Once that has healed, it will be redder than the rest of the skin. You will need to calm the tissue down as rapidly as possible to decrease the chance of that area developing post inflammatory hyperpigmentation or persistent erythema (leading to hypertrophic scarring).

Use mild to moderate topical steroids at the time - Hydrocortisone 1% ointment. If an area stays red for over 14 days, this is persistent erythema, and needs more aggressive therapy BID with a stronger topical steroid, eg. Elocon or Advantan or even a burst of systemic steroids. If it fails to respond try a topical ultra steroid, eg. Halciderm.

If the patient is developing areas of post inflammatory hyperpigmentation be sure and have them use a broad spectrum sunscreen, Retin A and hydroquinone. Keep in mind that a very light 10-15% TCA (exfoliation) peel will accelerate the lightening process.

BOTULINUM TOXIN FOR FUNCTIONAL FACIAL RHYTIDS

Facial wrinkles are frequently due to repeated muscle contraction. Botulinum exotoxin can produce weakness and paralysis of these muscles offering an alternative approach to the treatment of facial rhytids.

The effect, though temporary, is extremely popular with patients, has a low incidence of side effects and is a relatively easy technique to acquire. Botulinum Toxin has gained rapid and enthusiastic acceptance.

In 1985, 34 members of a music club in Elezelles, Belgium fell ill after consuming raw salted ham. Three of these people died. Subsequently Professor E. Van Ermengaen isolated the microbe that caused this illness. It was known as *Clostridium Botulinum*. The neurotoxin contained in this bacterium would be known as the strongest, most deadly poison known to man.

Attempts at purification began in 1920 by Dr Hermann Sommer. However, it was not until 1946 that type A toxin was purified in crystalline form. This work was done by Dr Edward Shantz at camp Detrick in Maryland. It was this wartime and post wartime historic work of Dr Shantz that laid the groundwork for our present day experience.

In the 1950's, Dr Vernon Brooks suggested the possible therapeutic application of the toxin in the treatment of hyperfunctional muscles. In the latter part of the 1960's it was Dr Alan Scott's search for a way to treat strabismus by muscle paralysis that brought him into contact with Dr Shantz and his toxin. Thus, the age of Botulinum toxin A began. It was not until 1978, Dr Scott began experiments on human subjects. In November 1979, Dr Shantz prepared a batch of crystalline Botulinum toxin A (batch 79-11) that until 1997 was the only batch to receive FDA approval and was the source of all Botulinum Toxin dispensed until the new batch was approved in 1997.

Botulinum toxin type A acts by preventing release of acetylcholine at the neuromuscular junction of striated muscle. The toxin is rapidly (within hours) and irreversibly bound to the presynaptic neuron at the neuromuscular junction. The Botulinum toxin is internalized and then acts as a zinc dependent endoprotease to disrupt the peptide necessary for acetylcholine release. This action may not be complete for two weeks and effectively destroys the affected neuromuscular junction, causing muscle paralysis. There is an ongoing turnover of neuromuscular junctions, however, that is enhanced by toxin exposure such that muscular function begins to return at approximately three months and is usually complete by six months.

Paralytic activity in the mouse is the mode of measuring strength of this toxin. One unit (U) is the amount of the toxin that kills 50% (LD50) of a standardized mouse model when injected intraperitoneally. This is affected by many factors-strain of mouse, housing conditions, etc.

Preparation and Dilution

I place the Botulinum Toxin in the fridge prior to reconstitution.

Diluent (normal saline) is added to reconstitute the toxin should be drawn into the vial by the vacuum and not squirted into the vial. The vial should not be shaken. Normal Saline with no preservatives is the manufacturers recommended diluent. Plain water results in an extremely painful injection. Some authors have reported no deleterious effects with preserved saline some have suggested the preservative could, at least partially deactivate the toxin. Alcohol to the cap should be allowed to fully evaporate, as it will inactivate the product. Once reconstituted, the product should be stored at 2-8 degrees C (refrigeration).

While the package insert recommend using the product within four hours, the actual longevity of activity, while controversial, appears to be much longer. Although some studies in the literature suggest as much as 44% loss of potency after 12 hours, others have shown no decrease in potency at 24 hours. In fact, recent studies have supported no decrease in potency after 30 days. This has been our personal observation having used the product after a period of 6 weeks personally with no obvious decrease in efficacy. We use the product over a 24 hour period. However, despite loss of potency, storage over 7-30 days poses potential problems with sterility as neither the product nor the saline is preserved.

Dilution

There is a wide variance in possible dilutions. Below is a table recommended for dilution purposes:

Diluent Added (0.9% Sodium Chloride Injection)	Resulting dose in Units per 0.1 ml
1.0 mL	10.0 U
2.0 mL	5.0 U
4.0 mL	2.5 U
8.0 mL	1.25 U

We use the dilution of 4.0 mls (injecting about 4.5 mls of Normal Saline to accommodate small amount lost in preparation) which gives us 25 U/mL. There is an area of denervation associated with each point of injection due to toxin spread of about 2.5-3.0 cm. While there are reversible and, rarely irreversible histological changes in muscles that are denervated after Botulinum Toxin there are no irreversible clinical effects.

Botulinum Toxin resistance is a concern for both the treating physician and patient. While many feel this could be due to large doses and/or increased frequency of injections, others do not support this position. The incidence only of 1-2% of treated patient's resistance (neutralizing antibodies). They could not unequivocally say this was due to the size or frequency of injection. We have never experienced resistance to Botulinum Toxin.

Injection Procedure

The frown is not a single corrugator muscle movement but a muscle mass movement of corrugator supercilliaris, procerus and obicularis oculi.

Individual doctors have individual approaches. The amount of Botulinum Toxin has variables eg male vs female, larger muscle masses etc. For a 20 unit injection our present approach is to use 4 mL dilution 25 U/mL and inject 0.8 mLs as follows using a 1 mL syringe and a 30 gauge needle:

Corrugator Frown Line

0.2 mL into either side of the central frown line (8.0 U). This is two injections on either side. 0.2 mL (4 U) into the procerus, midway between and slightly below the brows.

Crows Feet

Periorbital wrinkles are among the areas where Botulinum Toxin has been quite helpful. 1.0 mL Botulinum (0.5 mLs each side). Measure 1.5 cm from the lateral canthus and inject at this site and above and below. Always stay above the zygomatic arch. This gives a total of 20.0 U with 10.0 U each side. If a patient has redundant skin, again, be careful because the skin can end up folding over the zygomatic arch, producing an undesirable cosmetic effect. This technique is best for lateral and upper crows feet at rest. Eccymoses are common when treating periorbital wrinkles, so ice compresses are advised after each side is treated. Immediately after treatment, movement of the treated muscles is encouraged so the toxin is taken up by the involved neural end plates.

Forehead

5-8 injections of 0.2 mls- 0.125 mls (total 20.0) are placed across the forehead in the muscles in a uniform grid. Visible blebs are temporally produce upon injection. Remember that the brow shape can be changed because you are eliminating the major muscles responsible for elevating the brow. Injections in the forehead should be above the lowest fold produced when the patient is asked to elevate their forehead (frontalis). If the patient has a low eyebrow, treatment of the forehead lines should be avoided, or limited to that portion of the forehead 4.0 cms above the eyebrow.

Other Possibilities.

The platysma, especially the horizontal lines it creates can also be addressed with Botulinum Toxin therapy. Palmar, plantar and axillary hyperhidrosis are some of the newer treatments which have been found to be amenable to Botulinum Toxin therapy. There appears when treating sympathetic endplates such as hyperhidrosis to be a greater longevity of response than when treating those endplates with facial movement.

Botulinum Toxin works best in younger female patients (20-45 years of age). In some older patients and in some male patients, redundant skin can be created under the brow (pseudoptosis), so such patients should be approached with caution. In our experience a single treatment lasts 4-6 months.

APPENDIX

Information regarding Glycolic Acid

Patient Pre-Peel Instructions for AHA Peels

Peel Cautions for AHA Peels

Post peel Instructions for AHA Peels

Patient Information Regarding TCA Peels

Consent for Trichloroacetic Acid Peels

Instructions for Care during TCA Facial Peels

Taking Care of a TCA peel

Patient Information regarding Jessner Peels

Medical Treatment of Sun Damaged Skin

List of Medical Suppliers

~GLYCOLIC ACID~

Questions and Answers

WHAT IS GLYCOLIC ACID?

Glycolic acid is a natural ingredient that is derived from sugar cane and is a substance known as alpha hydroxy acid. Alpha hydroxy acids occur naturally in certain fruits and foods. For example, citric acid from citrus fruits, malic acid from apples, tartaric acid from grapes and lactic acid from sour milk. The most promising fruit acid for ageing and acne is glycolic acid because it has the smallest molecular size and therefore has a greater ability to be absorbed and utilised by the skin.

HOW DOES GLYCOLIC ACID WORK?

When we look at ageing skin, whether it is just beginning to be noticeable or ageing as it appears in mature skin, we visually perceive the result of sun damage that has manifested itself in a courser, thickened texture, enlarged pores, fine lines, deeper wrinkles and loss of underlying tissue tone and elasticity. Whether the changes are subtle or very noticeable, the cause is related to the gradual but increasing slowdown in the rate at which old cells leave the surface of the skin (stratum corneum) and are replaced by newer, younger cells. In addition, the underlying structure suffers from the sun's destruction of collagen and elastin resulting in distortions of the skin surface that we commonly refer to as wrinkles.

Glycolic acid works in two ways. First, glycolic acid loosens or dissolves glue-like substances that hold the outer layer of cells to each other and to the underlying epidermis (these thick, piled up, clinging cells are responsible for the appearance of dry skin, rough skin, scaly skin and brown age spots or brown sun damage spots). When the glue is loosened, the thick stratum corneum is sloughed away and the skin has a much smoother texture, refined pores and appears healthier, moist and more vibrant. Continued use prevents further skin thickening.

Secondly, glycolic acid is known to affect deeper levels of the skin by regenerating collagen and elastin. Clinical studies show a disappearance of fine lines and significant reduction of courser, deeper wrinkles.

And there is another equally important benefit: glycolic acid is proving to be more effective in removing brown sun spots or age spots than many of the other treatments currently being used.

GLYCOLIC ACID AND ACNE

Acne is caused by the abnormal keratinisation of cells in the follicle. Simply put, the same glue-like substance on the outer layer of the skin causes the cells in the follicle to stick together and plug the follicle instead of being expelled to the surface of the skin. When glycolic acid is used it also loosens the corneocytes (dead cells) in the follicle so that the follicle can clear. As the follicle clears, glycolic acid will also work to prevent a re-occurrence of the condition.

ARE THERE ANY SIDE-EFFECTS?

Glycolic acid does not make the skin more sun sensitive nor does it have the side-effects associated with Retin-A usage.

WHAT RESULTS CAN BE EXPECTED?

- Markedly softer, smoother texture
- Increased elasticity and firmness
- More refined, smaller appearing pores
- Moist, healthier, vibrant looking skin
- Lessening or complete disappearance of fine lines and reduction of deeper, coarser wrinkles
- Reduction and clearing of acne lesions, blemishes and blackheads
- Prevention of future lesions

HOW IS GLYCOLIC ACID USED AND APPLIED?

The key to the effectiveness of glycolic acid is how it is formulated and its ability to penetrate upon application. There are a number of preparations available for home use ranging from cleansers to treatment creams, gels and masks. These products can be integrated into existing skin care programs or used as a complete programme for maximum results (depending on skin type and condition).

Best results are obtained by weekly application of a Salon Peel containing higher percentages of glycolic for six to ten weeks, in conjunction with daily application of glycolic acid home care.

SAFE GLYCOLIC ACID PEEL

The glycolic acid peel treatment is like a light, safe chemical peel. Sensitivities vary and results and side effects run from ultra mild stinging to redness-mild flaking and peeling, all temporary, that last a few days at the most. Nearly all clients are able to apply make-up the next day.

INGREDIENTS

Out of all of the AHA's (alpha hydroxy acids or fruit acids) glycolic is the most potent in its capabilities for both desquamation(exfoliation) and improving the structural integrity of the skin far into the dermis. But, because of its random molecular motion, its good effects on the skin are often hit and miss. And when a glycolic acid molecule misses its mark, it will sometimes cause problems: hyper-pigmentation, hypo-pigmentation, blisters, rashes and breakouts.

To be more precise in its effect on the skin, researchers have been able to link glycolic acid molecules into stands to penetrate the skin along the lines of propagation of the skin's natural polymers- elastin and collagen. This new molecule, a glycolic polymer, once it is oriented to the skin's natural polymers, breaks into its individual molecular units and interacts more precisely with the skin's support structures.

When choosing an AHA treatment, ensure that all of the above information is covered and the glycolic acid has been 're-engineered' to be most effective.

PATIENT PRE-PEEL INSTRUCTIONS FOR AN AHA PEEL

1. Two weeks prior to your peel you should begin your regime of AHA home care twice daily. This will help acclimatise your skin in preparation for the peel.
2. For one week prior to the peel please STOP using the following treatments and products:
 - Electrolysis
 - Depilatories
 - Other peels or dermabrasion
 - Scrubs, loofa or other abrasive products
 - Permanent wave or straightening treatments
 - Waxing
 - Masks
 - Tretinoin (Retin-A)
 - Hair dying treatments

The use of these products/treatments prior to your peel may increase the reactivity of the skin to the glycolic acid.

3. We have reviewed your medical history and discussed the following areas:
 - Allergies
 - Medications used
 - Collagen disease/auto-immune disease
 - History of atrophic skin reactions: eczema, sebhorrheic dermatitis
 - Viral infections
 - Sun sensitivity

If there is any additional information in these areas that has not been discussed, please contact one of the doctors prior to your peel. As a reminder, if you do have a history of herpes simplex, you should be on preventative medication. The peel procedure can induce an episode of herpes lesions in patients who have had them previously.

4. On the day of the peel, please come to the surgery with a clean face. If possible, no make-up, cologne, or after-shave should be applied. Additionally, you should avoid shaving on the day of the peel if possible.

PEEL CAUTIONS

A skin peel is a complex procedure with certain inherent risks. If you follow your doctor's advice and directions the risk of complications in this procedure is small. Anything that you do against doctor's advice increases the chances of your having complications.

You will be well informed as to what you can and cannot do during your peel. It will be your responsibility to follow this advice since you will be caring for your skin at home.

There are certain conditions which may make you have to postpone your peel. These include:

- inflamed acne lesions
- open cuts and/or scratches on your face
- active cold sores on lips or face
- any facial surgery within 3 weeks, including "face lift" or eyelid surgery

In addition, if you are under severe physical or mental stress it is not a good time for a peel. It is important that you can devote all of your energies to your peel and are not distracted by other physical or mental needs.

It is extremely important that you do not pick, scratch, pull or rub your skin during your peel. If you do, you may damage the underlying new skin and cause changes in your pigmentation or scarring.

If, despite these warnings, you pick or rub your skin, you may ruin your peel. The doctor may elect not to do any further peels on you if he feels you will not follow his instructions exactly.

Please realise that these warnings are for your protection. The motto in this office is "if you are not sure if you should do something or don't understand the directions, always call the office before you do anything!!!! We never feel that any of your questions are "foolish" or "silly".

Consent form

CHEMICAL TRICHLOROACETIC ACID PEEL

I have had the risks and benefits of a chemical Trichloroacetic Acid Peel for my condition explained to me by _____ and I understand all the information that has been supplied.

(Patients Name)

(Patient's Signature)

(Date)

I have discussed the risks and benefits of a Trichloroacetic Acid Peel with this patient and have answered his/her questions and find him/her an appropriate candidate for treatment with a TCA peel.

(Doctor's Name)

(Doctor's Signature)

(Date)

INSTRUCTIONS FOR CARE DURING TCA FACIAL PEELS

- Use a mild soap to wash your face gently for 20 to 30 seconds twice a day. Lather the soap in your hands and gently pat the soap on your face, then splash lukewarm water unto your face to rinse off the soap. Dry your face gently patting it with a clean towel.
- Apply Hydrogen Peroxide 3% diluted (mixed half with clean water) after washing your face two times a day. Apply it by gently dabbing it on your face with cotton balls or gauze. It will bubble and may turn white. If hydrogen peroxide is too irritating and stings, you may dilute it even more with clean water. (Hydrogen peroxide reduces the chances of getting an infection).
- Apply healing cream morning and night.
- Apply Hydrocortisone Ointment as instructed. Apply the ointment gently, don't rub it in hard. You should use the ointment as often as necessary to keep your skin from getting dry and cracked. We'd rather you be too greasy than not greasy enough. Do not let your skin dry out, it will pull on the new tissue underneath and may cause red, irritated areas. You can apply your ointment ten times a day if you want! This will reduce the tightness and will make you more comfortable. Don't worry if all of the ointment doesn't come off when you wash your face, it won't harm you to leave some on your face. You may develop an occasional whitehead due to all the ointment on your skin. This is normal, do not be alarmed since they will resolve over time. Also, be aware that some mild itching and burning is normal at this time.
- Be sure and minimise facial expressions during your peel. Excessive facial movements will cause it to crack prematurely. This is not a good time to see a funny movie, or see your dentist.
- **DON'T PICK OR RUB YOUR SKIN AT ALL.** If you must wash your hair, wash it with your head tilted backward in the shower, or in the sink. Do not wet your face in the shower, too much water will cause you to peel prematurely and leave you with red, sore areas that may lead to scarring or need to be treated again. If large pieces of skin are hanging from your face, they may be cut off carefully with a pair of blunt-nosed scissors. Do not sit in a sauna or Jacuzzi at this time, or do strenuous exercise. Sweating will make your face sting and it will cause you to peel too soon.
- **DO NOT EXPOSE YOUR FACE TO SUNLIGHT AT ALL DURING THIS TIME.** If you feel you have to do some exercise, you may go out for a walk in the early morning or late evening when the sun is barely out.
- During your peel think of your dark old skin (which is peeling off) as a bandage which protects the fresh new skin underneath. The longer you can keep this natural bandage in place, the better results your peel will have.
- You may have some swelling during the first 2-3 days of your peel, particularly if it is a deeper peel. In extreme cases, your eyes may swell almost closed during the first two mornings. This is a normal response and it will resolve on its own.

However, sleeping with an extra pillow to elevate your head may help to decrease your swelling. **DO NOT APPLY ICE PACKS OR COLD COMPRESSES TO YOUR FACE TO DECREASE THE SWELLING.**

- It is important that you try to sleep on your back so you don't rub your peeling skin against the pillow. This could create an area of prematurely peeled skin.
- After the peel, sunscreen **MUST** be used to protect the skin from the rays of the sun. You need to use it even if you are wearing a hat, since the reflected rays may also cause damage. Please request sunscreen samples if they were not given to you before your peel.
- Make-up may be used 1-2 days after finishing the peel. We will recommend when you can wear it.
- If you have unexpected irritation or possible infection, call the office immediately! **DO NOT WAIT UNTIL YOUR NEXT APPOINTMENT.** This is especially important if you feel you may be developing a cold sore on your lip. The phone number is 9929 2566.
- If you are experiencing a lot of itching, be sure you use plenty of Hydrocortisone Ointment.

SUMMARY

You will continue to wash your face twice a day with soap and lukewarm water. Don't try to wash off every bit of your Hydrocortisone Ointment.

You need to use your daily healing cream throughout the peel, in the morning and evening.

You must keep your face very moist with Hydrocortisone Ointment.

You **MUST NOT** pick or rub your skin.

Do not go out in the sun at all while peeling - **EVEN FOR 5 MINUTES!** Do not use the cleaning or moisturiser routines as excuses to speed up peeling of your skin, it will only increase your risk of complications.

Do not be alarmed if when you bend over you feel flushed or warm. This is a temporary condition which resolves after the peel has healed completely.

If there are any problems or questions please contact the surgery on 9929 2566

JESSNER'S PEEL

Jessner's solution contains a combination of three active ingredients - lactic acid, salicylic acid resorcinol - all in low concentrations. It is a very safe, superficial peel and is the peel of choice for those who want the benefits of a fruit acid treatment, but would also like to see some flaking of the treated skin. Patients who would prefer to avoid flaking are recommended to have a series of glycolic treatments.

The Jessner's peel is suitable for those who want to freshen their complexion, restore lustre, reduce pigmentation, and improve acne blemishes and blackheads. It is possibly better than glycolic treatments for those with pigmentation problems.

For maximum benefit, it is recommended that you prepare your skin by using a product containing glycolic acid for two weeks prior to your peel. This preparation of the skin removes the first layers of dead skin cells, thus enabling the peel solution to penetrate more effectively, and is particularly important for patients with pigmentation problems. The most appropriate pre-peel products for you will be recommended by our medical aesthetician at your initial consultation.

The amount of peeling you experience can be adjusted to your needs. In general, the more flaking you can tolerate the faster you will see results. Our aesthetician will ask you how many days you wish to take for peeling and will adjust your peel to fit into this time frame as closely as possible. Even the lightest Jessner's peel will make the skin shiny and tight for a few days, though this can be camouflaged with make-up. Heavier peels will result in peeling for anything from a day or two up to a week. In addition, some patients experience red or brown streaking which disappears once the peeling is complete and is not cause for concern.

THE TREATMENT

After washing your face, our aesthetician applies the peel solution in coats. The more coats applied the heavier will be the peeling that you experience. Slight tingling or stinging may be experienced and you will find the cold air fan quite soothing. After the peel, your skin will feel tight and mask-like, so frequent use of a good quality moisturiser is helpful. **DO NOT PICK** at the peeling skin, as this will delay the healing, increases the risk of infection and compromises the final result. Allow the skin to flake away in its own time. Wash and shower as usual, being careful to dab the skin dry rather than rubbing it vigorously. Make-up can be worn over the moisturiser during the healing phase if desired. Do not use scrub, mask, astringent, toner, Retin-A or glycolic acid product during the healing phase. Resume use of these products 24-48 hours after the final flakes come away. It is most important to protect the skin from premature sun exposure by daily application of sunscreen containing titanium dioxide. This is particularly important for those prone to pigmentation problems. Often a series of Jessner's peels over several months is required to achieve the most optimal results.

Complications of Jessner's peels are very infrequent as the peel does not go deeper than the epidermal layer of the skin and of itself will not cause scarring. However picking or the occurrence of severe cold sore infection in the healing period could possibly lead to a permanent marking or a scar. Those very prone to cold sore infection should seek the advice of one of our medical practitioners before undergoing any peel. It is always a small risk that any peel on those who pigment very easily may cause reactive hyperpigmentation, which may require treatments with creams to lessen the

pigmentation over time. This problem is more likely if there is unprotected sun exposure within a month of a peel.

LIGHT CHEMICAL PEELING OR TCA PEELS

Your skin is a living organ made up of millions of cells. Every day thousands of cells die, fall off and are replaced by new cells from below.

Unfortunately, as we age, this becomes a slower and more haphazard process, making your skin unable to shed dark blotches, sun damage, or a dull, lifeless complexion.

The function of a skin peel is to create an even controlled shedding of several layers of damaged cells. This exposes a new, fresh layer of skin with a more even colour and a smoother texture. In addition, the peel stimulates new cells to grow, thereby tightening the skin, which decreases wrinkling.

There are several types of peels, each using a different chemical to create its peeling effect. Light and medium depth peels use the chemical TCA (trichloroacetic acid) to create their peel.

WHAT CAN A TCA PEEL ACHIEVE?

TCA peels can effectively improve many conditions, including:

- dull, weathered skin
- freckling
- blotchy pigmentation, including that resulting from pregnancy
- sun damage
- fine wrinkling
- shallow acne scars

TCA is a non-toxic chemical which has been used to perform skin peels for over 30 years. Unlike some other types of peel, TCA peels have the additional advantage of creating a fresh, natural appearing complexion, while preserving the normal skin colour. For this reason, they are often referred to as “freshening peels”.

Although one peel can significantly improve the appearance of the skin, some skin problems are deeper than others. It is possible that you may require more than one peel to achieve your best results.

If you decide that you are interested in a TCA peel, you will need to have a consultation with one of our doctors, who will examine your skin and discuss the potential benefits and risks of a TCA peel for your particular skin type and condition. If it is determined that you are a good candidate for this peel, some creams may be prescribed for you to use for a few weeks before your peel to prepare your skin for peeling.

HOW IS A PEEL PERFORMED?

TCA peels are performed right here in our rooms. A solution containing TCA is applied to your skin. This is usually associated with 2-3 minutes of a burning sensation. This burning is so brief that most patients choose not to use any sedation or anaesthesia.

WHAT HAPPENS TO MY SKIN DURING A TCA PEEL?

When TCA is applied to the skin, it causes the top layers of cells to dehydrate and peel off over a period of several days. When the old skin has peeled off, it exposes a new layer of undamaged skin which has a smoother texture and a more even colour.

HOW MUCH TIME WILL I MISS FROM WORK?

Most people take 5-7 days to heal from an average TCA peel. During the healing process there is no pain, but the skin looks as if it has had a severe sunburn. Therefore, most patients choose to stay at home during this healing time. However, if you are not too self-conscious about your appearance, you may be able to work during part of your peel.

HOW SOON CAN I RESUME MY NORMAL OUTDOOR ACTIVITIES?

Anyone who has a TCA peel is more sensitive to sunlight for at least 6-8 weeks after their peel. During this time it is very important to protect the new skin with sun screens, hats and the avoidance of strong sunlight. However, most people are anxious to protect their new improved skin from the damage of sun exposure and they continue to wear sunscreen daily even after they have healed completely.

ARE THERE RESTRICTIONS ON WHO CAN HAVE A TCA PEEL?

As with any procedure, not everyone is a candidate for a TCA peel. Unlike other peels, those done with TCA usually do not permanently lighten the skin. Therefore they can be performed on patients with darker skin types.

CAN TCA PEELS BE PERFORMED ON OTHER AREAS OF THE BODY BESIDES THE FACE?

Most people have similar ageing and sun damage on the neck, chest and hands as are present on the face. Fortunately, TCA peels can be performed successfully on these other non-facial areas as well.

WHAT ARE THE COMPLICATIONS?

Complications in this treatment are very infrequent. In the worst case a permanent mark or scar can result. This is extremely rare and when it occurs is normally related to an abnormality such as people who have a disorder of healing, picking or cold sore infection. If there is any persistently red area of skin which does not heal like other areas which have been peeled immediately, inform your treating doctor so corrective treatment can be performed.

In rare instances cold sore infection can be activated which may spread over the peeled area and in the worst case leave a scar. Those prone to cold sores may wish to commence a course of an antibiotic the day before the peel which usually suppresses the cold sore virus. More than one course of this medication may be required.

Peeling or picking the skin before it is ready to peel of its own accord will result in prolonged healing and possibly a permanent mark.

Reactive hyperpigmentation may occur, particularly in those who tan easily or if there is unprotected sun exposure within 2 months of the peel. It is virtually unknown that this does not totally respond to fading creams if treated when it appears.

POST PEEL INSTRUCTIONS

It may take up to one week for the appearance of your skin to return to “normal”. During the repair/renewal period you may, or may not, experience some of the following:

- Stinging, itching, burning, slight pain, tightness and peeling and scabbing of the superficial layer of the skin.

These sensations will gradually diminish over the course of the week as the skin returns to its normal appearance. If swelling occurs, use ice water compresses for 24-48 hours intermittently, as needed.

Following the guidelines set out below will help accelerate the renewal process.

- Apply a soothing moisturiser/emollient twice daily for 3-7 days until the skin returns to its normal appearance. Then restart your maintenance regime of AHA Home Care.
- Wash the treated area very gently.
- Do not use scrubs or abrasive products on the treated area.
- Avoid sun exposure.

TAKING CARE OF A TCA PEEL

The most important concept in healing from this type of face peel is to allow the old, chemically “burnt” skin to stay in place, as a bandage, as long as possible. Anything that promotes premature peeling of this skin will increase the chances of complications.

With this basic rule in mind, post-peel care is very easy to understand.

The daily routine of skin care is listed on the “Instructions for care During Facial Peels”. In summary it states:

- 1) The face is washed gently twice a day (with a mild cleanser) to remove excess medications, dirt and debris from the skin. It is not necessary to remove all traces of previously applied medications.
- 2) After washing, the skin is then treated with a 3% hydrogen peroxide compress to kill bacteria growing on the skin. Many times the patient will have to dilute the peroxide to half strength (with clean water) to decrease its tendency to sting and burn.
- 3) A soothing “daily” lotion containing $\frac{1}{2}$ - 1% hydrocortisone is then applied to “calm” the skin and decrease itching and redness.
- 4) An ointment is then applied to keep the skin soft and pliable and to prevent cracking and premature peeling of the skin. We usually use 1% hydrocortisone ointment to help decrease the itching.

There are several rules for behaviour during the healing process:

1. Washing
 - Wash gently - don't use washing as an excuse to accelerate the peeling process
 - Don't use a washcloth - lather the soap on your hands and gently apply it to your face.
 - Don't let the shower beat on your face - have it hit your back or chest.
 - If you wash your hair, wash it with your head tilted backward in the shower after ointment has been applied to your face.

2. Medications
 - Only use what the doctor has given you - you can easily react to many of your normal products during the peel.
 - Gently dab medications on your face - don't try to rub them in, you may accidentally dislodge the peeling skin.
 - Keep the skin very moist with ointments, so it won't dry out and peel prematurely or begin to itch.
 - Don't touch your face except when applying medications.

3. Exercise
 - Avoid sweating - it creates stinging and itching and may soak off the old peeled skin.
 - Patients who want to exercise can take a leisurely walk in the early morning or late evening, while wearing a broad-brimmed hat.
 - Remember, being outdoors during sunny hours is dangerous to your peel even with a hat or visor, since 50% of the UV light can be reflected upwards from the ground.
 - Remember, UVA (tanning ray) goes through glass, so it is necessary to avoid exposure to direct sunlight even through glass when healing from a peel.
 - Avoid sunlight for 2-3 months after a peel - it may feel hot and uncomfortable, and it can create dark blotches on your new skin.

4. Sleeping
 - Try to sleep on your back to avoid rubbing your face into the pillow and peeling prematurely (it may help to put pillows on either side of your body to prevent you rolling over).
 - If you have a good deal of facial swelling during the first two days you can sleep with an extra pillow, or sleep sitting up in a lounge chair.

5. Activities
 - Excessive stretching of the skin (ie. hearty laughter, eating a large sandwich, or going to the dentist) may cause premature peeling of the skin and lead to the formation of scars.
 - You are welcome to leave the house as long as you don't sweat, exercise heavily, go in the sun, or excessively move your facial muscles.

Medical Treatment of Sun-Damaged and Wrinkled Skin

While some “wrinkle creams” can briefly improve appearance by hydrating the stratum corneum (the outer horny layer of the skin) or slightly decreasing inflammation. This merely temporarily covers up the signs of aging without truly reversing them.

There have been recent advances in creams available that have been clinically proven to improve the signs aging both clinically and histologically. This is primarily done by reversing photodamage.

Each individual patient requires an individual regime of skin care depending on skin colour, sun damage and age. Your physician will tailor an appropriate regime.

Alpha hydroxy Acids

These are often referred to as fruit acids. They occur naturally from certain fruits such as citrus, grapes and apples. The most popular is glycolic acid which is derived from sugar cane.

Glycolic acid works in two ways. It loosens and dissolves glue-like substances that hold the outer layer of cells to each other and to the underlying dermis (these thick piled-up clinging cells are responsible for the appearance of dry skin, rough skin, scaly skin and brown age spots or brown sun damage spots). When the glue is loosened, the thickened stratum corneum is sloughed away and the skin has a much smoother texture, refined pores and appears healthier, moist and more vibrant. Continued use prevents further skin thickening.

Secondly, Glycolic acid is known to affect deeper levels of the skin by regenerating collagen and elastin. Clinical studies show a disappearance of fine lines and a significant reduction of coarser, deeper wrinkles.

Glycolic acid is the most effective cream for removing sun spots or age spots. Results to be expected are:

- Softer, smoother texture
- Increased elasticity and firmness
- More refined, smaller appearing pores
- Moist, healthy, vibrant skin
- Lessening or complete disappearance of brown spots and/or sun spots
- Marked reduction and disappearance of fine lines and reduction of deeper, coarser wrinkles
- Reduction and clearing of acne lesions, blemishes and blackheads
- Prevention of future lesions

Retin A

Retin A has been available for twenty years. It triggered a revolution in non-surgical treatment of sun damaged skin. Considerable scientific research shows that it improves the histological signs of photoageing and photodamage. What does Retinoic Acid actually do?

1. Thins and compacts the stratum corneum resulting in a smoother softer skin texture
2. Thickens the epidermis causing the skin to tighten
3. Removes actinic keratoses (rough blotches of the skin from sun damage)
4. Disperses melanin (pigmentation) improving brown blotchy skin
5. Stimulates dermal collagen tightening the skin and removing fine wrinkles
6. Stimulates new blood vessels giving the skin a pinker, rosy hue

Retin A does have some adverse reactions. Initial treatment may make the skin red peeling and sensitive. This can be treated by starting slowly, say every second night until your skin becomes accustomed to it. It may also make the skin more sun-sensitive so sun avoidance is very important. People that tend to have ruddy complexions with superficial fine blood vessels may find the Retinoic acid accentuates this problem. Retin A can only be prescribed by a doctor because of the possible risk of systemic absorption and effect on unborn children in pregnant women.

Hydroquinone

This is often termed a bleaching agent. They are not true bleachers. Hydroquinone acts by preventing the melanocytes producing melanin. (the pigment in the skin responsible for brown sun spots and freckles). When used with glycolic acid and Retin A the cells turn over more rapidly and the brown spots will fade. Hydroquinone is used frequently after facial peels and laser resurfacing to prevent hyperpigmentation. The Elizabeth Cosmetic Centre provides a physician strength hydroquinone not available commercially.

Sun Avoidance and Sunscreen

This is the most important component to prevent further sun damage and for the treatment of sun-damaged skin. It has been shown that simply avoiding the sun can reverse the histological signs of photo damage. In other words, the skin has the ability to repair itself if it is protected from continual photodamage. No matter what treatment regime you decide, further exposure to the sun will reverse any good effects and continue with the damage. It is impractical, almost impossible, to totally avoid the sun so we must settle for the next best thing - sun protection. This includes hats and protective clothing and sun screens.

The easiest and most reasonable protection for most people is sunscreen. Sunscreen should be worn every day, whether you are outdoors a little or a lot. Because UV damage is cumulative in its effects, even the prevention in small amounts of sun damage over a long period of time can have a profound impact on the total amount of UV-induced damage.

The daily use of a broad-spectrum sunscreen is imperative in the treatment of photodamaged skin. It is important to apply sunscreen to all exposed areas of the neck, chest and dorsum of hands. Sun Protection Factor gives a guide to the strength of the sunscreen applied. SPF 16 is quite adequate for every day use. It is important you find a sunscreen you are happy with and use it regularly.

Galderma

Key areas/information, which are required, are as follows:

Supply Agreement:

- Practitioner's details and clinic details
- Valid Australian Business Number
- Valid Medical Registration Number
- Trade References not required however if not supplied the account will automatically default to pre-paid
- All pages are to be initialed and followed by the signature of Practitioner, Witness and Director/Partner where applicable.
- All pages of the Supply Agreement are to be returned

Letter of Understanding:

- Valid Medical Registration number
- Document is to be signed by the Practitioner
- All pages to be returned
- Dr is to provide us with a copy of Medical Board Certificate of Registration (APHRA check not accepted).

If you have any questions at all regarding the agreement or the letter of understanding please don't hesitate to contact us at Customer Service on 1800 144 944.

Note: Completed paperwork can be returned to us either by:

Fax: 1800 151 496

Email: queries.au@galderma.com

Allergan

To be able to purchase Allergan products (ie BOTOX® & JUVEDERM®), Doctors need to complete on-line training modules & attend one of our Training workshops. No other previously completed aesthetic training courses will enable a Doctor to open an account with Allergan.

Contact Lia Pin-DiMascio – Training Coordinator

pin-dimascio_lia@allergan.com

02 9498 0132

Merz

Merz is able to supply registered Doctors

True Solutions

15-17 Merton St
Zetland 2017
T: 1800 808 993
E: info@true-solutions.com.au
W: www.true-solutions.com.au

Neostrata

Hamilton Laboratories
217 Flinders St
Adelaide 5000
T: 1800 882 592
E: info@purist.com
W: www.neostrata.com

Neutrogena - Johnson &

Johnson

Locked Bag 5
Broadway 2007
T: 0413 263 256
W: www.neutrogena.com

Ego Pharmaceuticals

21-31 Malcolm Road
Braeside, Victoria 3195
Phone: 1800 033 706 / 9955 8688

Allergan Australia

77 Ridge Street
Gordon, NSW 2072
Tel: 1800 252 224
www.informedbeauty.com.au
tel: +61 2 9498 0290
fax: +61 4 1962 2145
mobile: +61 2 9498 0100

Sanofi Aventis

12-24 Talavera Rd
Macquarie Park 2113
T: 02 9422 6333
Email: peter.hensley@sanofi-aventis.com

Australian Medical Aesthetics

Unit 21, 45-51 Huntley Street
Alexandria 2015
T: 02 9557 4461
M: 0400 802 790
E: dani.ama@bigpond.net.au

Galderma Division

Suite 4, 138 Narabang Way
Belrose NSW 2085
T: 1800 144 944
M: 0432 616 600
E: Cherie.cleland@galderma.com
W: www.galderma.com.au

Australasian Medical and Scientific Ltd

Unit 2, 19-21 Gibbes St
Chatswood, NSW, 2067
T: 02 9882 3666
W: www.amsl.com.au
W: www.justbeautiful.com.au

Merz Australia Pty Ltd

Bill Diamond, National Sales Manager
M: 0488 122 283
E: Bill.Diamond@merz.com
W: www.merzaesthetics.com.au

BIBLIOGRAPHY and RECOMMENDED READING

RUBIN, MARK. MANUAL OF CHEMICAL PEELS. J.B.LIPINCOTT COMPANY
1995. PAGES 110-124, 130-153

KLEIN, ARNOLD. BOTULINUM TOXIN AND COLLAGEN FOR THE AGING
FACE. PAGES 23-28. COSMETIC SURGERY, AUGUST 1998

BRODY, HAL CHEMICAL PEELING MOSBY YEARBOOK 1992

KOTLER, ROBERT. CHEMICAL REJUVENATION OF THE FACE. MOSBY
YEARBOOK 1992

MOY, LAURENCE SUPERFICIAL CHEMICAL PEELS WITH ALPHA
HYDROXY ACIDS. COSMETIC CUTANEOUS. CHAPTER 32.

A	
Allergic Reactions	48
Alpha Hydroxy Acids:	14
APPENDIX	59
Assessment	8
C	
CLASSIFICATION OF	
PHOTODAMAGE	5
Classification of Skin Types	3
Combination Therapy:	18
D	
DYSCHROMIA	5
G	
GLYCOLIC ACID AND ACNE	71
GLYCOLIC ACID PEELS	21
GLYCOLIC ACID~	71
H	
Hypopigmentation	47
I	
INSTRUCTIONS FOR CARE DURING TCA	
FACIAL PEELS	60
Introduction	2
J	
JESSNER'S PEELS	27
Junctional Naevi:	6
K	
KEY POINTS TO REMEMBER	58
L	
Lentigines Simplex:	6

LIGHT CHEMICAL PEELING OR TCA	
PEELS	64
M	
Melasma:	7
O	
Other Non-Peel Methods:	20
P	
PATIENT SELECTION	53
Patients With Sensitive Skin	13
PEEL CAUTIONS	66
Persistent Erythema	48
POST PEEL INSTRUCTIONS	67
POST PEEL PROBLEMS:	59
Postinflammatory Hyperpigmentation	45
Postinflammatory Hyperpigmentation:	7
R	
Retinoic Acid	11
REVERSAL OF PHOTODAMAGE WITH	
CHEMICAL NON PEEL	
TECHNIQUES	9
S	
Scarring	49
Seborrheic Keratoses:	6
SUMMARY	61
T	
TAKING CARE OF A PEEL	68
TRICHLOROACETIC ACID PEELS	32
U	
Using Glycolic Acid Products:	16